

Histology, Hyperglycemia and Dyslipidemia Evaluations of Aqueous Extract of *Moringa oleifera* Leaves on Adult Wistar Rat.

*Oboma, Yibala .I¹ and Asuqwo E.E²

*Department of Medical Laboratory Science, FBMS, CHS, Niger Delta University Wilberforce Island Bayelsa State. yoboma@yahoo.com,
+2347030244521

Department of histopathology, University of Calabar Teaching Hospital Calabar,
Cross River State,
edemasq69@yahoo.com

ABSTRACT

Chronic hyperglycemia is an indicator of diabetes mellitus and chronic dyslipidemia a risk factor cardiovascular disease.

OBJECTIVE: We aim at evaluating the effect of *Moringa oleifera* on glucose level, lipid profile, cardiac markers, liver enzymes, proteins and histology of the heart and liver.

METHODOLOGY: Twenty six male (26) adult Wistar rats were enrolled for the study. Acclimatized and randomly divided into four groups (A, B, C&D, n=6) and controls. They rat were given intraperitoneal injection of aqueous *Moringa oleifera* leaf extract. Sacrifice was carried out on 24hrs, 7days, 14days, and 28days respectively. Tissues collected were prepared for histology using heamatoxylin and eosin staining techniques while serum lipid profile, glucose level, creatine kinase, malondialdehyde (MDA) and liver enzymes were analyze using Selectra and micro Elisa.

RESULT: High doses (500mg/kg) and prolonged exposure to the extract resulted in spectrum effects. Prolonged and increase concentration of extract administration causes increase in body weight and is statistically significant at $P<0.05$, $t=35$ and $df=8$, decrease in lipid profile, creatine kinase (CK-MB), malondialdehyde (MDA), liver enzymes and glucose at both higher and lower doses of 500mg/kg and 300mg/kg respectively. Photomicrograph with magnification of x400, show normal histology of the heart and liver.

CONCLUSION: Aqueous leaf extract of *Moringa oleifera* show a potential anti-hyperglycemia and antilipidemic properties with no notable hepatotoxicity and cardiac injury. This study supports the popular sayings about the tradomedicinal use of *Moringa oleifera* in the treatment of diabetes mellitus and hypertension.

Keywords: cardiovascular disease, diabetes mellitus, *Moringa oleifera*, hyperglycemia.

Introduction

The therapeutic use of *Moringa oleifera* in the Indian subcontinent dates back to antiquity and other parts of the world and sub-Saharan Africa in particular. The use appears not to have been known by the wide public as it is being promoted by diverse organizations as an untapped opportunity [14,15]. In many regions of Africa, it is widely consumed for self-medication by patients infected with diabetes, hypertension and HIV/AIDS [7]. Chronic hyperglycemia is an indicator of diabetes mellitus (DM), and chronic dyslipidemia a risk factor for cardiovascular disease (CVD). These metabolic disorders are global epidemics [16, 18]. In developing countries they are on the way to becoming a major causes of morbidity and mortality as infectious diseases due to the progressive transition in these countries to a life style characterized by greater access to dietary calories and less demand or calorie expenditure [1]. Geographically many developing countries are located in the tropical and sub-tropical regions of the world where *Moringa oleifera* grows and is cultivated. If *Moringa oleifera* is validated by medical science, dietary consumption of this plant could be advocated in our countries as an inexpensive prophylactic strategy against DM and CVD. The aim of this work is to evaluate the effect of aqueous leaf extract of *Moringa oleifera* on the glucose level, lipid profile, Cardiac markers and liver enzymes of adult Wistar rat and to assess the effect of the aqueous leaf extract on visceral organ (Liver and heart). All the data are expressed as Mean \pm SD. Statistical analysis was done by Students t-test and one way ANOVA.

Material and Methods

Extract Preparation

Cold extraction of *Moringa oleifera* was carried out at room temperature (18°C-22°C) following the method of Atawodi *et al.*, 2010[3]. 500g of the paste was put in a standard volumetric flask and covered with 1000mls of distilled water and stopper with cotton wool and allowed to stand at room temperature for 48hrs for complete

extraction. The aqueous extraction was filtered off into pre-weighed evaporating dishes. The filtrates were evaporated into a syrupy residue using a rotary extractor at 40°C. The extract was pooled together into an airtight container and stored refrigerated at -4° C until required for use.

Extract Administration

Fresh preparation was made on each day of the experiment and the resulting solution inserted intraperitoneally into albino Wistar rat.

Administered volume = $\frac{\text{Effective Dose (ED)}}{\text{Stock solution}}$

Stock solution

Effective dose = Dose assigned to each group

Stock solution = 500mg/ml of distilled water.

Animal Handling and Management

Twenty six (26) male adult Wistar rats were randomly divided into four groups (A, B, C, & D., N=6) and 2 Controls (Diabetic and Non-diabetic controls). Group A and B were subjected to glycemic control studies. The sugar level was measured in Group A and B after inducing diabetic and *Moringa oleifera* administered from day 0, 7days, 21days and 28days, compared with the diabetic control group. Lipid profile, Creatinine kinase, Malondialdehyde activities was measured in group C and D compared with the non-diabetic control while liver enzymes was measured in all the groups and compared with the negative control.

Inducement of Diabetes

Diabetes was induced by a single intraperitoneal injection of freshly prepared streptozotocin (STZ) at the dose of 55 mg /kg in 0.1 M citrate buffer (pH 4.5) to the control group of overnight fasted rats.

Collection of Samples

The blood samples were collected by Cardiac puncture under chloroform anesthesia into fluoride oxalate contains (for blood sugar) and into sterile container. The blood samples in the sterile bottles was allowed to clot and retracted at room temperature. Sera were separated into plastic vials and stored in the freezer (- 20°C) until required for use. During biochemical assays the sera was allowed to thaw at room temperature. Animals sacrifice was by cervical dislocation in stages. The organs (Liver and Heart) were removed at necropsy and fixed in 10% buffered neutral formalin and stained with heamatoxylin and eosin staining technique.

Instrumentations and Equipments

Automatic tissue processor (Leica TP 1020), Embedding panel (Leica EG 1160), Microtome (Leica RM 2125), Selectra PRO-s, Chemistry system, Elitech Clinical System, AKA, Elitech GRP, Made in USA, Micro Elisa, Water bath, Digital weighing balance, conical flask, Digital microscope, Automatic pipettes and light microscope.

Histological Method

Tissues were sectioned at 4µm on a Rotary microtome (Leica RM 2125) and stained with Ehrlich's heamatoxylin and eosin method for microscopy. The processing of the tissue carried out in Niger delta university Okolobiri while photomicrography was taken in the department of Anatomical pathology, Niger Delta University, Wilberforce Island bayelsa state.

Biochemical Assay

Serum Alanine amino transferase (ALT) and Aspartate amino transferase (AST), Total protein, Albumin, Serum creatine kinase –MB (CK-MB), Plasma malondialdehyde (MDA), Glucose and Lipid profile was done using Selectra PRO-s, Chemistry system, Elitech Clinical System, USA, Eli and micro ELISA. Serum Low Density Lipoprotein Cholesterol (LDL-C) Mulder *et al* 1984 method, LDL – C in plasma = Total cholesterol – 1.3 × supernatant cholesterol (mMol/L).Serum High Density Lipoprotein Cholesterol (HDL-C) Level(Dextran Sulphate Precipitation method), Estimation of Total Cholesterol, Triglycerides (Colorimetric enzyme method), Serum Estimation of Albumin (Colorimetric Bromocresol Green method pH 4.2), Serum Estimation of Total Protein(Biuret End point), Estimation of Serum Alkaline Phosphate(Based on Dakc and SCE method), Estimation of Serum Alanine amino transferase(AST) and Aspartate amino transferase(IFCC method with Pyridoxal phosphate -P-5-p), Serum High Density Lipoprotein Cholesterol (HDL-C) Level, Dextran (Sulphate Precipitation method), while Malondialdehyde is by non-enzymatic per oxidation method.

Results

Table 1 show the body weight gain (d/l), (final weight/28 per day) of the animal after administration of the extract)compared with control. There is a corresponding increased in final weight and the weight gain compared with control and was statistically significant at p<0.05, t=35 and DF=8. Values were expressed as mean ±SD using graph pad prism 5.

Table 2 express Mean glucose concentration following administration of extract for 0, 7, 21, and 28 days. The result shows a reduction in mean glucose concentration from the 7th day through 28th of extract administration in both group A and B compared with control. Comparison between group A and B compared with control (at 500mg/kg) show a significant value at $p < 0.05$, q value 4.0, mean difference 30 for group A and q value of 3.3, and mean difference of 25 for group B and both were statistically significant.

Table 3 show serum lipid profile:-Total cholesterol (TC), Triglycerides, (TG) low density lipid cholesterol (LDL-C) and high density lipid cholesterol (HDL-C) estimations in group C and D compared with control. There was a drop in the serum lipid profile of group C and D compared with control and was statistically insignificant.

Table 4 show serum creatine kinase –MB (CK-MB) and malondialdehyde enzyme activity after 28 days administration of extract values expressed in mean \pm SD. There was a drop in serum enzyme activity and insignificant at $p < 0.05$ compare with the control.

Table 5 show liver enzymes, total protein and albumin reduction of group A, B, C and D when compared to normal. Values expressed in Mean \pm SD

DISCUSSION

Moringa oleifera is an edible plant with a wide range of nutritional and medicinal values been attributed to its roots, leaves, barks, flowers, fruits, and seeds,[2] thus the need for this research on the glycemic, Lipidemic and histological (heart and liver) assessment of the aqueous leaf extract. Intraperitoneal administrations of different concentration of aqueous extract of *Moringa oleifera* was given to the Wistar rats followed by standard diets for a maximum of 28 days. Positive and negative controls were used. Administration of aqueous extract of *Moringa oleifera* for 28 days causes an increase in body weight (Body weight gain g/dl= final body weight- initial body weight). The body weight was statistically significant and this could be attributed to anabolic steroid found in the extract. De-piccolli et al.,[19] reported that steroid are used to stimulate bone marrow and growth, lean body mass and also play role in the prevention of bone loss even in the elderly and this agree with the present study.

Intraperitoneally administration of aqueous leaf extract of *Moringa oleifera* lowers blood glucose concentration even at the first seven days of administration with a direct proportionality to dosage. The effect was more pronounce on 500mg/kg for 28 days duration compared with doses of 300mg/kg and control and this could be attributed to the presence of alkaloids in the leaves. Alkaloids in the leaves of *Moringa oleifera* was reported to mediate the hypoglycemic effect of the plant and more recently the effect was further explored using HFD-fed insulin –resistant C53L16 mice taking an estimated daily dose of 386mg/kg in drinking water for 17weeks comparing with untreated controls, the mice gain weight and had reduced fasting random glucose level and equally plasma total cholesterol [5]. Jain et al., [6] has estimated the LD dose of ethanol leaf extract of *Moringa oleifera* and found to be more than 2600mg/kg and less than 5000mg/kg and thus increasing dose of *Moringa oleifera* within the defined doses may be considered beneficial. Furthermore the chlorogenic acid in the extract can beneficially affect glucose metabolism and has been shown to inhibit glucose-6-phosphate translocase in rat liver, reducing hepatic gluconeogenesis and glycogenolysis [9] as seen in the study. *Moringa oleifera* contains phytosterols such as beta-silosterol [6] and this compound can reduce intestinal uptake of dietary cholesterol [12]. This may partly account for the decrease in plasma cholesterol in this study. They exists a pronounce reduction in total cholesterol, triglycerides, low density lipid cholesterol, high density lipid cholesterol at concentration of 500mg/kg compared with control. Flavonol quercetin is found at concentration as high as 10mg to 100g of dried *Moringa oleifera* leaves-predominantly as quercetin -3-o- β -D-glucoside also known as isotrifolin [11]. Quercetin is a potent antioxidant [17] with multiple therapeutic properties with anti dyslipidemia, hypotensive and antidiabetic effects on obese Zucker rat [13] and reduction of atherosclerosis in HCD and HFD rabbits [8].

Oxidative stress is widely accepted as a major contributing factor in the pathology of diabetic mellitus and cardiovascular disease [4]. Results from this study confirmed that higher doses of aqueous extract of *Moringa oleifera* significantly reduced serum creatine kinase CK-mB activities and malondialdehyde when compared with control. This suggests that intraperitoneally administration of *Moringa oleifera* increases the antioxidant potential of antioxidant enzyme activities as a protective mechanism against oxidative stress agreeing with the works of Atawodi et al., [3]. Also the viability and functionality of a cell depends on a favorable redox state that is on its ability to preventive excessive oxidation of macromolecules including DNA, proteins and lipid [20]. A recurring explanation for the therapeutic action of *Moringa oleifera* medication is the relatively high anti oxidant activity of its leaves, flower, seeds and roots [3]. Obviously this is seen on the histology of the liver and heart of the wistar rats of the present study as Heamatoxylin and Eosin staining reaction show a normal heart and liver architecture compared with control.

Liver enzymes such as Aspartate amino transferase (AST), Alanine amino transferase (ALT), Alkaline Phosphate, (ALP), Total protein (TP), and albumin are marker for liver function and integrity (20). These enzymes are usually elevated in acute hepatotoxicity or mild hepatocellular injury and membrane damage as a

result of oxidative stress variety of cytosolic enzymes are release into the blood stream [20]. The biochemical analysis of serum liver enzymes from this study shows significant decrease in levels of all the enzymes, total protein and albumin assayed when compared with normal showing membrane protective of *Moringa oleifera* confirming *Moringa oleifera* to reduce oxidative stress on visceral organs

CONCLUSION

The study revealed that doses of 300mg/kg and 500mg/kg of aqueous leaf extract on *Moringa oleifera* have no negative effect on the liver and heart morphology rather shows protective effects. The study further highlight the potential ability of high doses of aqueous extract of *Moringa oleifera* in the treatment of diabetics, and cardiovascular, and hepatic related disorder as confirmed by the chemical and histological evaluation.

RECOMMENDATION

Further studies on immunology, histology and histochemistry may be needed for further study. Human model experiment should be established in Bayelsa state, South- South Nigeria.

ACKNOWLEDGMENT

We acknowledged MIs Agu Charles, Department of histopathology Niger Delta University Teaching Hospital Okolobiri and the CEO/MD of Oaks diagnostic laboratory Bayelsa State.

Conflict of interest and sponsorship- NIL

REFERENCES

- [1] Aje, T.O., Miller, M. Cardiovascular disease: a global problem extending into the developing world. *World J. Cardiol.*2009, 1:3–10.
- [2] Anwar, F., Latif, S., Ashraf, M., and Gilani, A. H. *Moringa oleifera*: A food plant with multiple medicinal uses. *Phytotherapy. Res.* 2007, 21:17–25
- [3] Atawodi, S. E., Atawodi, J. C., Idakwo, G. A., Pfundstein, B., Haubner, R., Wurtele, G., Bartsch, H., Owen, R. W. Evaluation of the poly phenol content and antioxidant properties of methanol extracts of the leaves, stem, and root barks of *Moringa oleifera* Lam. *Journal of Med. Food.*2010,13: 710–716.
- [4] Dhalla, N. S., Temsah, R. M., Netticadan, T. Role of oxidative stress in cardiovascular diseases. *J. Hypertens* 2000,18: 655–673.
- [5] Iffiu-Goltesz, Z., Wanecq, E., Lomba, A., Portillo, M. P., Pellati, F., Szoko, E., Bour, S., Woodley, J., Milagro, F. I., Alfredo Martinez, J., Valet, P., Carpena, C. Chronic benzylamine administration in the drinking water improves glucose tolerance, reduces body weight gain and circulating cholesterol in high fat diet-fed mice. *Pharma. Res.* 2010,61:355–363.
- [6] Jain, P. J., Patil, S. D., Haswani, N.G., Girase, M. V., and Surana, S.J. Hypolipidemic activity of *Moringa oleifera* Lam., Moringaceae, on high fat diet induced hyperlipidemia in albino rats. *Braz. J.Pharmacog.* 2010, 20: 969–973.
- [7] Kasolo, J. N., Bimenya, G. S., Ojok, L., Ochlenq, J., Ogwal-Okeng, J. W. Phytochemical and uses of *Moringa oleifera* leaves in Ugandan rural communities. *J. Med. Plant Res.* 2010, 4: 753–757.
- [8] Kamada, C., da Silva, E. L., Ohnishi-Kameyama, M., Moon, J. H., and Terao, J. Attenuation of lipid peroxidation and hyperlipidemia by quercetin glycoside in the aorta of high cholesterol-fed rabbit. *Free Radi. Res.* 2005;39: 185–194
- [9] Karthikesan, K., Pari, L., and Menon, V.P. Antihyperlipidemic effect of chlorogenic acid and tetrahydrocurcumin in rats subjected to diabetogenic agents. *Chem. Biol. Interact.* 2010a; 88: 643–650.
- [10] Karthikesan, K., Pari, L., and Menon, V. P. Combined treatment of tetrahydrocurcumin and chlorogenic acid exerts potential antihyperglycemic effect on streptozotocin-nicotinamide-induced diabetic rats. *Gen. Physiol. Biophys.* 2010b, 29: 23–30.
- [11] Lako, J., Trenery, V. C., Wahlqvist, M., Wattanapenpaiboon, N., Sotheeswaran, S., and Premier, R. Phytochemical flavonols, carotenoids and the antioxidant properties of a wide selection of Fijian fruit, vegetables and other readily available foods. *Food Chem.* 2007, 101: 1727–1741.
- [12] Lin, X., Racette, S. B., Lefevre, M., Spearie, C. A., Most, M., Ma, L., and Ostlund, R. E. Jr. The effects of phytosterols present in natural food matrices on cholesterol metabolism and LDL-cholesterol: a controlled feeding trial. *Eur. J. Clin. Nutr.* 2010, 64: 1481–1487.
- [13] Rivera, L., Moron, R., Sanchez, M., Zarzuelo, A., and Galisteo, M. Quercetin ameliorates metabolic syndrome and improves the inflammatory status in obese Zucker rats Obesity. *Silver Spring* 2008, 16: 2081–2087.
- [14] Thurber, M. D., and Fahey, J. W. Adoption of *Moringa oleifera* to combat under nutrition viewed through the lens of the “diffusion of innovations” theory. *Ecol. Food Nutr.* 2009, 48: 212–225
- [15] Torimiro, D. O., Odeyinka, S. M., Okorie, V. O., and Akinsuyi, M. A. Gender analysis of sociocultural perception of *Moringa oleifera* amongst farmers in south-western Nigeria. *J. Int. Womens Stud.* 2009, 10: 188–202.
- [16] Yusuf, S., Reddy, S., Ounpuu, S., Anand, S. Global burden of cardiovascular diseases: Part II: variations in cardiovascular disease by specific ethnic groups and geographic regions and prevention strategies. *Circulation* 2001, 104:2855–2864.
- [17] Zhang, M., Swarts, S. G., Yin, L., Liu, C., Tian, Y., Cao, Y., Swarts, M., Yang, S., Zhang, S. B., Zhang, K., Ju, S., Olek, D. J. Jr., Schwartz, L., Keng, P. C., Howell, R., Zhang, L., Okunieff, P. Antioxidant properties of quercetin. *Adv. Exp. Med. Biol.* 2011, 915: 283–289.
- [18] Wild, S., Roglic, G., Green, A., Sicree, R., King, H. Global prevalence of diabetes: estimates for the year 2000 and projections for 2030. *Diabetes Care.* 2004, 27: 1047–1053.
- [19] De-picolli B, Giada F, Benettin A, Sartori F and Piccolli E. “Anabolic steroid use in body builders. An echocardiographic study of left ventricle morphology and function”, *International Journal of Sports medicine*, 1991, 12: 12-408
- [20] Rao A V, Rao L G. (2007), “Carotenoids and human health”, *Pharmacological research.* , 2007, 55: 16-207.

Table No. 1 Effects OF Moringa Oleifera leave Extract on Adult Wistar Rats Body Weight after 28 Day.

Group A	125±1.3	204±2.3	2.8±0.2
Group B	123±2.3	225±2.5	2.8±0.8
Group C	122±1.4	236±1.8	4.0±0.1
Group D	187±1.5	240±2.4	1.8±0.4

Values were expressed as mean ± SEM, n = 5 for each group (control and treatment) Body weight gain g/d = Final body weight – Initial body weight (g) ÷ 28.

Table NO. 2 Mean Glucose Concentration following Extract Administration for 0, 7, 21 and 28 days.

GROUPS	DAYS			
	0	7	21	28
Control	61.8±1.6	85.8±31.3	89.6±3.5	91.7±4.1
Group A	64.6±1.8	53.1±3.5	47.7±2.7	43.8±2.5
Group B	67.5±1.3	58.2±1.3	54.8±1.2	49.5±1.2

Values were expressed as mean ± SEM

Group A = 500mg/kg – High concentrated.

Group B = 300mg/kg – less concentrated. Control – 1ml of saline after diabetic inducement.

Table NO. 3 Serum Lipid Profile at 28 Day of Administration

Group mg/kg	TC - Mmol/L	TG - mMol/L	LDL - C mMol/L	HDL - C Mmol/L
Control	2.93±0.20	1.87±0.01	1.97±0.01	2.40±0.02
Group C	1.82±0.20	1.10±0.02	0.75±0.01	2.53±0.01
Group D	2.25±0.10	1.44±0.10	1.04±0.02	3.05±0.02

Values were expressed as mean ± SEM

Control – Non diabetic, 1ml of saline

Group C – 500mg/kg

Group D – 300mg/kg

TABLE NO. 4 Serum Creatine Kinase – MB (CK – MB) and Malondialdehyde Activity at 28 Days of Extract Administration

Groups mg/kg	CK - MB (μL)	MDA (μmol/L)
Control	122 ± 1.0	3.60 ± 0.1
Group C	97 ± 0.2	2.30 ± 0.0
Group D	90 ± 0.1	1.60 ± 0.0

Values were expressed as mean ± SEM

Control – Non diabetic, 1ml of saline

Group C – 500mg/kg

Group D – 300mg/kg

TABLE NO. 5 Serum ALP, AST, ALT, TP AND ALBUMIN after 28 DAYS OF extract administration

Parameters	ALP	AST	ALT	TP	ALBUMIN
Control	280.0±2.0	37.0±1.0	39.0±0.0	9.0±0.1	5.0±0.2
Group A	200.0±1.0	20±2.0	23±1.0	7.6±0.2	4.2±0.6
Group B	168.0±2.0	18±3.0	19.0±1.0	7.4±0.1	4.1±0.5
Group C	140±3.0	17±2.0	12±2.0	8.2±0.2	3.8±0.2
Group D	191±0.0	21±2.0	18±3.0	7.0±0.2	2.9±0.1

Values were expressed as mean ± SEM

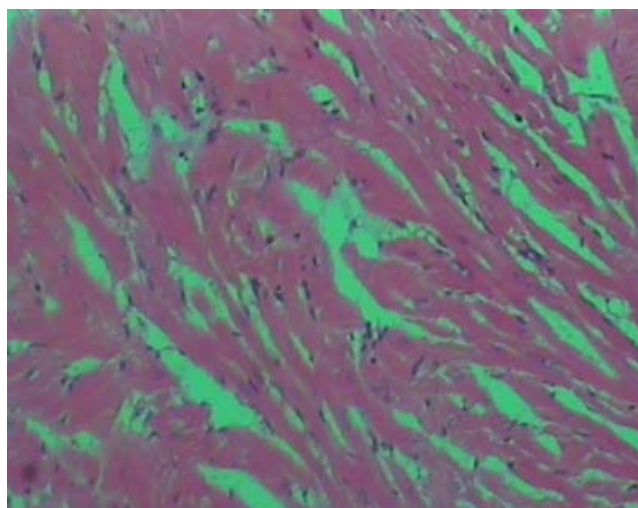
Control – Non diabetic, 1ml of saline

Group C – 500mg/kg

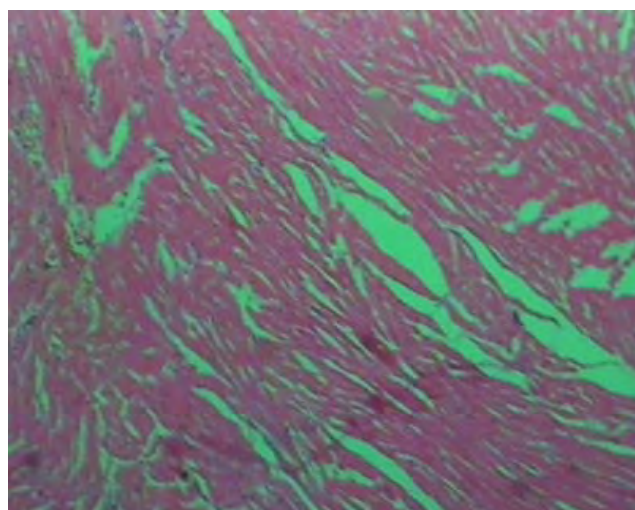
Group D – 300mg/kg

Histology of the heart and liver following 500mg/kg body weight of aqueous leaf extract of *Moringa oleifera* for 14 and 28 days.

HISTOLOGY OF THE HEART

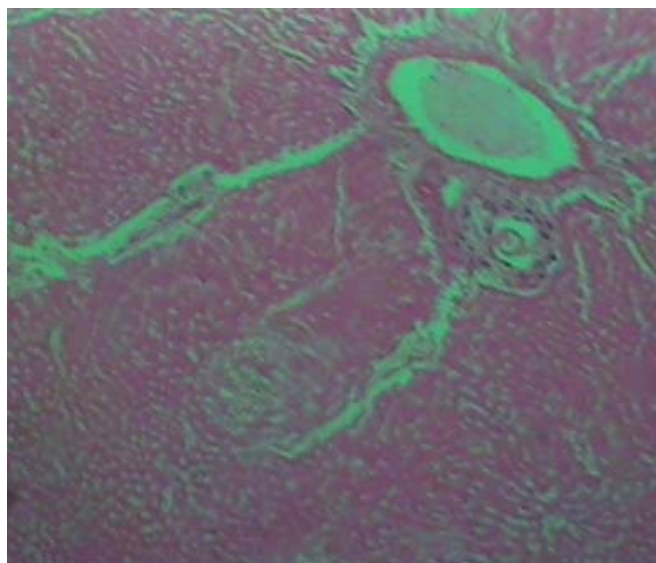


A X400

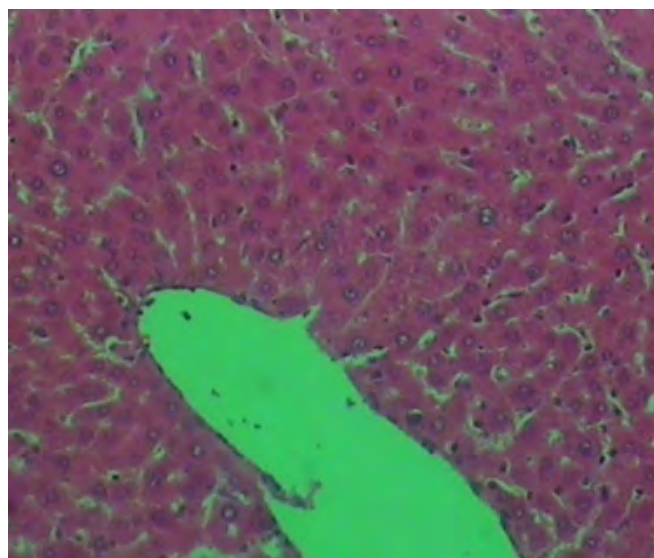


BX400

LIVER HISTOLOGY



CX400



D X400

Photomicrographs of liver and heart after administration of aqueous extract of *Moringa oleifera* leaves showing normal heart tissue (A&B), with spindle cell shapes and normal intraseptae space following intraperitoneal administration 500mg/kg bodyweight for 14days and 28days respectively while C&D shows normal liver tissue with normal central vein, sinusoid and portal triad.