

Use of A Very Low Dose of Streptozotocin To Induce Diabetic Retinopathy in Rats

IRAWATI IRFANI^{1,2*}, ARIEF S. KARTASASMITA^{1,2}, RIA BANDIARA^{3,4}, A.PURBA⁵

¹Department of Ophthalmology, Faculty of Medicine, Universitas Padjadjaran Bandung, Indonesia

²Cicendo National Eye Hospital, Bandung, Indonesia

³Hasan Sadikin General Hospital, Bandung Indonesia

⁴Department of Internal Medicine, Faculty of Medicine, Universitas Padjadjaran Bandung, Indonesia

⁵Department of Biomedical Science, Faculty of Medicine, Universitas Padjadjaran, Bandung, Indonesia

Phone number: +62224210883

Email: irawati.irfani@unpad.ac.id

ABSTRACT - Background:Diabetic retinopathy is chronic disease involving retinal neuronal structural changes and retinal vascular system disorders. Animal models were modified in order to study the changes in diabetic retinal layer. Variable methods were used on animal models to induce diabetes with Streptozotocin. The purpose of this study was to determinewhethermultiple, very low-dose streptozotocin (STZ) administration would induce diabetic retinopathy in rats,and be associated with a lowermortality rate than the conventionalSTZ injection model of diabetes.**Methods:**Twenty-four male Wistar rats were divided into a control group (I), a multiple low-dose STZ group (II), and a single, high-dose STZ group (III). Their blood glucose concentrations were measured regularly. After 6 weeks, only rats from groups I and II survived. The thickness of their retinal layers and theirretinal ganglion cell (RGC) morphology were then analyzed.**Results:**Hyperglycemia was present in groups II and III bythe third day after STZ injection. Rats in group II survived and demonstrated stable high blood glucose concentrations during the 6 weeks of the study. Thinning of the retinal nerve fiber layer (group I: $2.30\pm 0.911\ \mu\text{m}$ vs.group II: $1.17\pm 0.394\ \mu\text{m}$, $p = 0.010$) and derangement of the retinal ganglion cellsby score parameter were found in the low-dose STZ group(group I: 2.50vs. group II 1.00, $p = 0.010$)**Conclusion:** Multiple lowdoses of STZ were effective at inducingearly diabetic retinopathy. Thinning of the nerve fiber layer and derangement of the ganglion cell layer were detected 6 weeks after injection.

Keywords: very low-dose streptozotocin,diabetic retinopathy, nerve fiber layer, ganglion cell

INTRODUCTION

Diabetic retinopathy is a chronic, progressive disease that impacts retinal neuronal structure and the retinal vascular system. The number of patients with diabetic retinopathy is predicted to increase from 100.8 million in 2010 to 154.9 million in 2030. Furthermore, 30% of diabetic retinopathy patients will subsequently develop blindness,^{1,2} making it the leading cause of blindness worldwide. Therefore, appropriate animal modelsof diabetic retinopathy are essential to facilitate the study of the disease, and its treatment and prevention.

Streptozotocin (STZ) induces hyperglycemia in animals by destroying pancreatic β -cells, leading to the development of type 1 diabetes-like clinical pathology and signs.³Numerous variations inthe dose and route of administration for STZ have been used for this purpose in rats. One of the most common protocols is the injection of a single high dose of STZ (40–70 mg/kg of body mass).^{4,5} However, this protocolcancause massive β -cell necrosis and a sudden release of insulin,which results in fatal hypoglycemia.⁶Another commonvariant is the use of multiple, lowdoses of STZ, administered for 5 consecutive days,which is associated with a lower degree of toxicity than the single high-dose protocol. However, although the choice of protocol depends on the study objectives, even the multiple low-dose protocol is associated with significant adverse effects, and a milder version may still be effective at inducing diabetic retinopathy. Thus, the most appropriate dose regimenfor the induction of diabetic retinopathy by STZ remains to be established.

Studiesof rats using single, high doses of STZ showed progressive thinning of the ganglion cell layer and the retina as a whole, along with reductions in the number of retinal ganglion cells present.^{7,8}However, there have been no studies that have compared the efficacy of very lowdoses of STZ for the induction of diabetic retinal changes in rats. Therefore, the aim of this study was to determine whether very low doses of STZ would be effective at inducing diabetic retinopathy, while reducingthe mortality rate of the rats used.

MATERIALS AND METHODS

Animal procedures

This study was conducted using 24 male Wistar rats (*Rattus norvegicus*), aged 10–12 weeks, and weighing 250–300 g. The procedures used followed the national and institutional guidelines for the care and use of laboratory animals and were approved by the ethics committee of the Faculty of Medicine, Universitas Padjadjaran (No. 287/UN6.C.10/PN/2017). The rats were housed in a ventilated room under a 12h light/dark cycle, with *ad libitum* access to food and water, and were acclimated for 3 days before use. They were allocated to three groups: a control group (group I), a low-dose STZ-treated group (group II), which was intraperitoneally injected with 40 mg/kg STZ (mixed anomer, lot no. M6P1705) dissolved in 1 ml of citrate buffer (pH 4.5) on 2 consecutive days, and a high-dose STZ-treated group (group III), which was injected with 60 mg/kg as a single dose. The control group was injected with an equivalent volume of citrate buffer alone. The rats in groups II and III were provided with 10% dextrose water for 5 days after being injected with STZ. Peripheral blood samples were drawn from their tail veins, and blood glucose was quantified using an Easytouch® GCU hand-held glucose meter before STZ injection, 3 days after injection, and every 2 weeks thereafter. Diabetes was defined by a blood glucose concentration > 250 mg/dL. Body mass was also measured at the indicated times. After 42 days, the rats were euthanized by carbon monoxide inhalation, and both eyes were dissected and stored in 10% formalin for subsequent histologic evaluation.

Retinal preparation and examination

The eyes were embedded in paraffin blocks with the corneas facing upward. Coronal sections were prepared at 4 μ m using a keratome, placed in a waterbath, mounted on microscope slides, dried, and stained with hematoxylin and eosin (HE). Three visual fields were examined from the caudal part of each retina by a certified anatomic pathologist, who evaluated the retinal layers and ganglion cells using an image multiplier light microscope (Olympus BX21) at $\times 200$ magnification. Images were captured using dotSlide (Olympus Soft Imaging Solutions, GmbH) and an XC10 Olympus camera. The thicknesses of each layer of the retina (nerve fiber, inner plexiform, inner nuclear, outer plexiform, and outer nuclear layers) were measured, and the mean values were calculated for each group. Retinal ganglion cells were evaluated with regard to their density per high-power field and cellular morphology (regularity, swelling, and vacuolation). Each parameter was assessed using a 0–5 scale, as explained in the legend to **Table 1**.^{9,10} Statistical analysis was performed using the unpaired *t*-test and Mann-Whitney U-test, with $p < 0.05$ being considered to represent statistical significance.

RESULTS AND DISCUSSION

In both STZ-treated rat groups, elevated blood glucose levels were detected on day 3 after the first STZ injection. The mean levels of blood glucose indicated on days before and after STZ injection are shown in **Fig. 1** and **Fig. 2**. All blood glucose levels in the STZ-treated rat group were elevated to more than 250 mg/dL. Unfortunately, four days after injection, all samples in group III died. On week 6, the blood glucose level of rats injected with a low dose of STZ stabilized at 494.75 mg/dL (**Fig. 1**).

The characteristics of rats at pre-injection and 6 weeks' post-injection in the control group and low dose STZ treated group are presented in **Table 2**.

The retinal layers of enucleated eyes from the control group and low-dose STZ group were analysed. The mean thicknesses of each layer of the retina were measured and compared using unpaired T-test and Mann-Whitney test. The mean thicknesses of the retinal layers in both groups are shown in **Table 3**.

Ganglionic cell arrangement was evaluated according to its density and score parameter in **Table 1**. Mean retinal ganglion cell (RGC) density and RGC arrangement are shown in **Table 4**. Differences in RGC regularity, number of swollen cells, and vacuole formation between control and low-dose STZ-treated rats are shown in **Fig. 3**.

Peritoneal STZ injection damages pancreatic β -cells and reduces the production of insulin, which is required for blood glucose regulation.^{11,12} Rats injected with STZ generally show an increase in blood glucose within 2–3 days.¹³ In this study, an increase in blood glucose was measured from day 3 after the first STZ injection, and the concentration stabilized at a high level, as shown in **Fig. 1**. The blood glucose concentrations achieved in the present study fulfilled the criterion for diabetes in rats, reaching >250 mg/dl blood glucose within 48 h.¹³⁻¹⁵ During the 6 weeks of the study, the blood glucose concentrations remained >250 mg/dL, representing chronic hyperglycemia and diabetes (**Table 2**).

The increase in blood glucose in group I was substantial, and the provision of 10% dextrose solution did not affect this. Indeed, 4 days after intraperitoneal injection of the high dose of STZ, all the rats had died. High mortality has frequently been noted following the injection of a high dose of STZ, due to massive β -cell islet necrosis and the sudden release of insulin, which typically causes fatal hypoglycemia within 48 h of the injection. One method that has been used to prevent this is the provision of 10% sucrose water. In their study, Furman *et al.* administered 1 ml of 5% glucose solution intraperitoneally 6 h after STZ injection, or provided

10% sucrose water for 2 days, but both procedures were still associated with a mortality rate of > 20% after a single, high-dose STZ injection.⁶ Thus, the present study and previous studies demonstrate that severe or fatal hypoglycemia is likely to occur following the injection of a single, high dose of STZ.⁶

By contrast, in the multiple, low-dose STZ-treated group, the rats survived the full 6 weeks of the study. In this group, 10% dextrose water was provided for 5 days after the first STZ injection. STZ injections were administered for 2 consecutive days, and on day 3 the blood glucose concentration had increased, after which it stabilized at a high level for the remainder of the study, without any further intervention being required.

Multiple, low-dose STZ injection for 5 consecutive days is a widely used method of inducing diabetes in rodents. In this protocol, hyperglycemia is achieved due to damage to the pancreatic islets, which initiates an inflammatory process that causes further loss of β -cell activity. This results in insulin deficiency and hyperglycemia. Compared with the effect of the single, high-dose STZ protocol, this response is closer to the pathogenesis of type 1 diabetes. Here, we have shown that the administration of a low dose of STZ for only 2 consecutive days also induces hyperglycemia. Three weeks after STZ injection, more than 50% of the animals had developed severe hyperglycemia, with blood glucose concentrations of 300–600 mg/dL.¹⁵ Previous studies of diabetic complications that have used a multiple low-dose STZ model have usually involved the administration of a second round of STZ injections during week 7. However, in the present study, the blood glucose concentrations of the rats were still high 6 weeks after induction, and early changes consistent with diabetic retinopathy were detectable.

Long-term hyperglycemia may lead to microvascular complications, including diabetic retinopathy.^{1,8,11} The characteristic retinal abnormalities are initially neuronal, with thinning of the retinal layers (nerve fiber layer, ganglion cell layer, inner retinal layer (plexiform and inner nuclear), and outer retinal layer (plexiform and outer nuclear)).^{3,7,12} Previous studies have shown that diabetes is associated with greater apoptosis in neurons. This mainly occurs in the internal retinal layer, where the ganglion cells originate. Up to 10 times as many neuronal as non-vascular retinal tissues undergo apoptosis, implying that apoptosis occurs earlier in neurons than in vascular cells. Furthermore, the degree of apoptosis in neurons is concomitant with the duration of the disease.¹² Neurons are unable to proliferate; therefore, apoptosis causes chronic neurodegeneration and diminution of the thickness of retinal layers.

We studied retinal tissue 6 weeks after low-dose STZ to determine its early effects on the retinal layers. Six weeks was chosen as the end-point on the basis of prior observations of deficits in retinal function and vision, indicated by diminution in electroretinogram (ERG) responses and impairment in the optokinetic nystagmus test, respectively, in Long-Evans rats 4 weeks after STZ administration.¹³ In this study, thinning of the nerve fiber layer and derangement of the retinal ganglion cells were significant in group II ($p = 0.010$). However, the density of retinal ganglion cells per high-power field was not affected by prior STZ injection (group I: 25.4 ± 4.0 vs. group II: 24.3 ± 9.4).

In the present study, the inner and outer retinal layers were thicker in the low-dose STZ-treated rats, possibly due to Muller cell inflammation and swelling, rather than edema.¹⁶ A previous study showed a significant reduction in the thickness of the retinal nerve fiber layer and significant increases in the thickness of the inner plexiform and nuclear layers.¹⁷ However, in this study, no differences in the overall thickness of the retina were found between the control and low-dose STZ-treated groups. This finding was in contrast to those of a 35-week study of diabetic rats, which showed thinning of the ganglion cell layer and a reduction of up to 10% in the number of retinal ganglion neurons compared with normal rats. The thicknesses of the inner nuclear layer and the inner plexiform layer were 22% and 14% lower than in the control group, respectively, while those of the outer plexiform and outer nuclear layers were similar.^{3,7,12} In the present study, which modeled the early phase of diabetes-induced retinal pathology, the inner retinal layer was thickened, probably due to Muller cell inflammation and swelling.¹⁶ However, when diabetes is more established, the thickness of the inner retinal layer begins to decrease, due to the loss of ganglion cell bodies and death of the neurons and glial cells.⁷

This study evaluated the early changes in the retina during the development of diabetes in rats. Nerve fiber layer thinning and derangement of RGCs were observed 6 weeks after the induction of diabetes using very low-dose intraperitoneal STZ, corroborating the findings of a previous study that demonstrated neuronal damage in the retina during the early phase of diabetes, manifesting in a reduction in nerve fiber layer thickness and ganglionic cell density.¹³ In addition to this loss of density, the ganglion cells were disordered, swollen, and vacuolated in the retinal ganglion cell layer.

The principal limitation of this study was that a retinal examination was not conducted in the high-dose STZ group, because 3 days of hyperglycemia was considered too early for diabetic complications to have developed. Many variations of the STZ diabetes induction protocol have been used, in terms of dose, route of injection, and the need for subsequent insulin injections.^{6,14,15} However, the present study has shown that two low-dose injections of STZ administered on consecutive days is capable of inducing early retinal changes characteristic of those present in diabetes within 6 weeks.

CONCLUSION

This study has described a method of inducing stable hyperglycemia and early diabetic retinopathy in male Wistar rats 6 weeks after the administration of two low doses of STZ. The early changes in the retina consisted of thinning of the nerve fiber layer and derangement of the ganglion cell layer. These findings support the contention that the prevention of retinal complications should be instituted before vascular abnormalities are detected on funduscopic examination, considering that neuronal damage in the retina is an early consequence of diabetic hyperglycemia.

ACKNOWLEDGEMENT

Funding. The authors hereby acknowledge receipt of a Universitas Padjadjaran Research Internal Grant for this study.

Author contributions. Category 1 (a) Concept and design: all authors; (b) acquisition of data: II; (c) analysis and interpretation of data: II. Category 2 (a) drafting of manuscript: II, ASK (b) revisions for intellectual content: all authors. Category 3 (a) final approval: ASK.

Non-author contributions. Authors hereby acknowledge Hasrayati Agustina, who served as participating investigator and Adinda C.D. Nugraheni, who participated in the writing and technical editing of the manuscript.

CONFLICT OF INTEREST

The authors declare that they have no conflict of interest.

REFERENCES

- [1] Sitompul R. Retinopati Diabetik. J Indon Med Assoc. 2011; 61: 377-41.
- [2] Ciudin A, Hernández C and Simó R. Molecular implications of the PPARs in the diabetic eye. PPAR research. 2013; 2013.
- [3] Kern TS and Barber AJ. Retinal ganglion cells in diabetes. The Journal of physiology. 2008; 586: 4401-8.
- [4] Laaboudi W, Ghanam J, Ghoumari O, Sounni F, Merzouki M, Benlemlih M. Hypoglycemic and hypolipidemic effects of phenolic olive tree extract in Streptozotocin diabetic rats. Int J Pharm Pharm Sci. 2016; 8(12): 287-291
- [5] Kanhere RS, Reddy KR, Jayveera KN. Evaluation of Anti-diabetic potential of Ixora Pavettain Streptozotocin induced Diabetic rats. Int J Pharm Pharm Sci. 2015; 7(4): 230 - 236
- [6] Furman BL. Streptozotocin-induced diabetic models in mice and rats. Current protocols in pharmacology. 2015; 70: 5.47: 1-5.
- [7] Barber AJ, Lieth E, Khin SA, Antonetti DA, Buchanan AG and Gardner TW. Neural apoptosis in the retina during experimental and human diabetes. Early onset and effect of insulin. Journal of Clinical Investigation. 1998; 102: 783.
- [8] Simó R and Hernández C. Neurodegeneration in the diabetic eye: new insights and therapeutic perspectives. Trends in Endocrinology & Metabolism. 2014; 25: 23-33.
- [9] El-Bakary AA, El-Dakrory SA, Attalla SM, Hasanein NA and Malek HA. Ranitidine as an alcohol dehydrogenase inhibitor in acute methanol toxicity in rats. Human & experimental toxicology. 2010; 29: 93-101.
- [10] Setiohadji B, Irfani I, Rifada M, Virgana R and Kartasmita AS. The Superoxide Dismutase Mimetic TEMPOL and Its Effect on Retinal Ganglion Cells in Experimental Methanol-Intoxicated Rats. Ophthalmology and Therapy. 2018; 1-6.
- [11] Uthra S, Raman R, Mukesh BN, et al. Genetics of diabetic retinopathy. International Journal of Human Genetics. 2008; 8: 155.
- [12] Barber AJ, Gardner TW and Abcouwer SF. The significance of vascular and neural apoptosis to the pathology of diabetic retinopathy. Investigative ophthalmology & visual science. 2011; 52: 1156-63.
- [13] Aung MH, Kim MK, Olson DE, Thule PM and Pardue MT. Early Visual Deficits in Streptozotocin-Induced Diabetic Long Evans Rats STZ-Induced Visual Defects. Investigative ophthalmology & visual science. 2013; 54: 1370-7.
- [14] Vaishya R, Singh J and Lal H. Biochemical effects of irbesartan in experimental diabetic nephropathy. Indian journal of pharmacology. 2009; 41: 252.
- [15] Deeds M, Anderson J, Armstrong A, et al. Single dose streptozotocin-induced diabetes: considerations for study design in islet transplantation models. Laboratory animals. 2011; 45: 131-40.
- [16] Barber AJ. Diabetic retinopathy: recent advances towards understanding neurodegeneration and vision loss. Science China Life Sciences. 2015; 58: 541-9.
- [17] Vujosevic S and Midena E. Retinal layers changes in human preclinical and early clinical diabetic retinopathy support early retinal neuronal and Müller cells alterations. Journal of diabetes research. 2013; 2013: 905058

TABLE 1. SCORES FOR RETINAL GANGLION CELL ASSESSMENT

Histopathological Observations of Retinal Ganglion Cells	Score
Retinal ganglion cell layers	
Normal structure* and no swelling**	5
Structure abnormality < 50%, 20% cells with swelling, and vacuoles < 50%***	4
Structure abnormality 50-80%, < 50% cells with swelling, and vacuoles < 50%	3
Structure abnormality >80%, < 50% cells with swelling, and vacuoles < 50%	2
Structure abnormality >80%, > 50% cells with swelling, and vacuoles > 50%	1

* Structure – Regular ganglion cells well arranged in linear, with no aberrant cells apparent.

** Swelling – Ganglion cells appear significantly edematous.

*** All percentages are estimated from the means of three high power fields in each slide.

TABLE 2. CHARACTERISTICS OF CONTROL AND LOW-DOSE STZ-TREATED RAT GROUPS

Variable	Group	
	Control n=8	Low-dose STZ-treated n=8
BW pre-injection (gram)	291.75±23.407	274.12±14.075
BW on week 6 (gram)	331.37±28.106	228.62±46.182
Blood glucose pre-injection (mg/dL)	77.00±7.289	73.87±6.446
Blood glucose on week 6 (mg/dL)	90.62±8.314	496.87±132.618
Δ blood glucose (mg/dL)	13.62±11.927	423.00±128.562

TABLE 3. THICKNESSES OF RETINAL LAYERS FROM CONTROL AND LOW-DOSE STZ-TREATED RAT GROUPS

Variable (µm)	Group		p-value
	Control n=8	Low dose STZ-treated n=8	
Nerve Fiber Layer			0.010**
Mean±Std	2.30±0.911	1.17±0.394	
Range (min-max)	1.33–3.77	0.59–1.74	
Inner Plexiform			0.529
Mean±Std	44.27±12.165	46.41±10.963	
Range (min-max)	28.62–63.36	35.69–63.31	
Inner Nuclear			0.163
Mean±Std	27.75±4.685	33.97±10.663	
Range (min-max)	21.85–36.82	23.40–51.97	
Outer Plexiform			0.725
Mean±Std	8.26±2.698	8.77±2.916	
Range (min-max)	4.95–12.54	5.37–13.60	
Outer Nuclear			0.101
Mean±Std	54.09±5.635	59.46±6.552	
Range (min-max)	42.69–61.02	52.44–67.44	
Overall Retinal Thickness			0.267
Mean±Std	157.00±24.952	173.23±30.899	
Range (min-max)	131.68–209.66	108.50–218.59	

Note: ** p-values <0.05 were considered significant

TABLE 4. RGC DENSITY AND RGC ARRANGEMENT IN CONTROL AND LOW-DOSE STZ-TREATED RATS

Variable	Group		p-value
	Control n=8	Low-dose STZ-treated n=8	
Density of RGC			0.760
Mean±Std	25.37±3.961	24.25±9.407	
Range (min-max)	21.00–33.00	9.00–37.00	
Cellular arrangement of RGC			0.010**
Median	2.50	1.00	
Range (min-max)	1.00–4.00	1.00	

Note: ** p-values <0.05 were considered significant

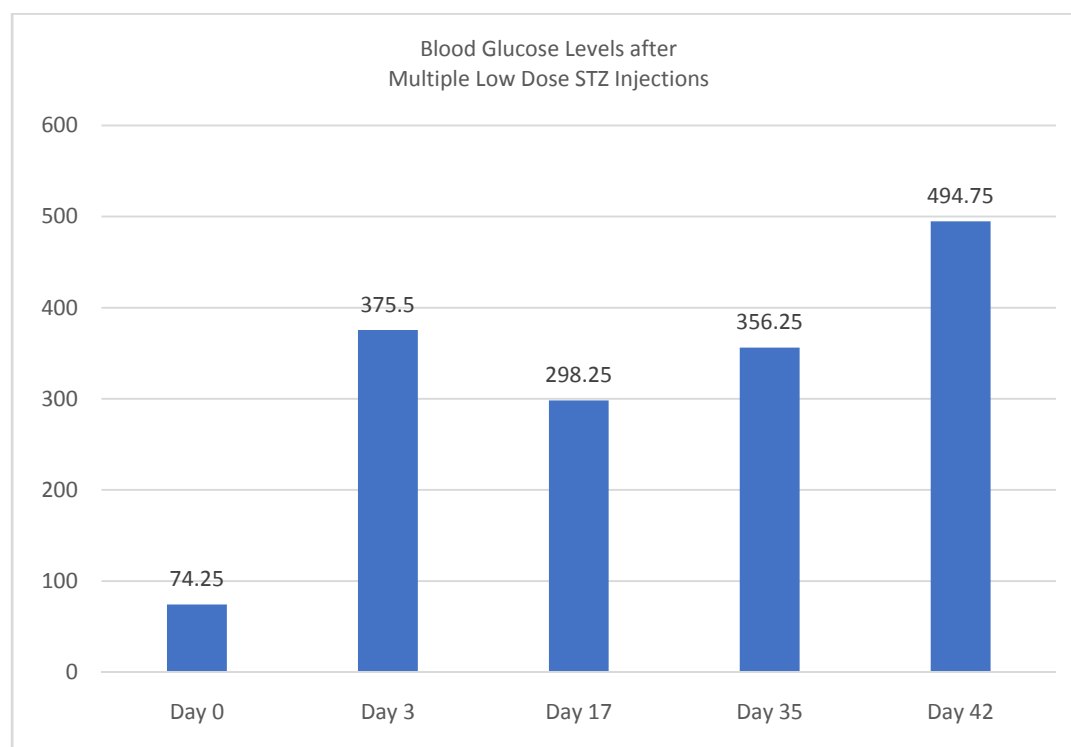


FIG. 1. LOW-DOSE STZ INDUCED HYPERGLYCEMIA IN RATS. BLOOD GLUCOSE LEVELS WERE MONITORED BEFORE AND AFTER STZ INJECTION ON THE INDICATED DAYS.

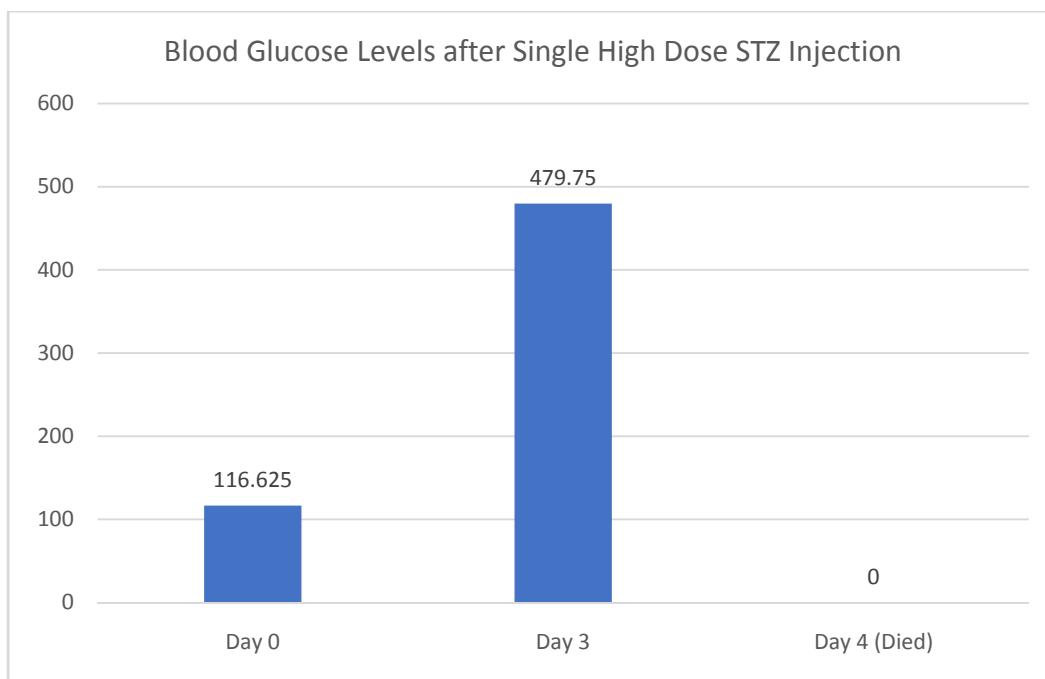


FIG. 2. HIGH-DOSE STZ INDUCED HYPERGLYCEMIA IN RATS. BLOOD GLUCOSE LEVELS WERE MONITORED BEFORE AND AFTER STZ INJECTION ON THE INDICATED DAYS.

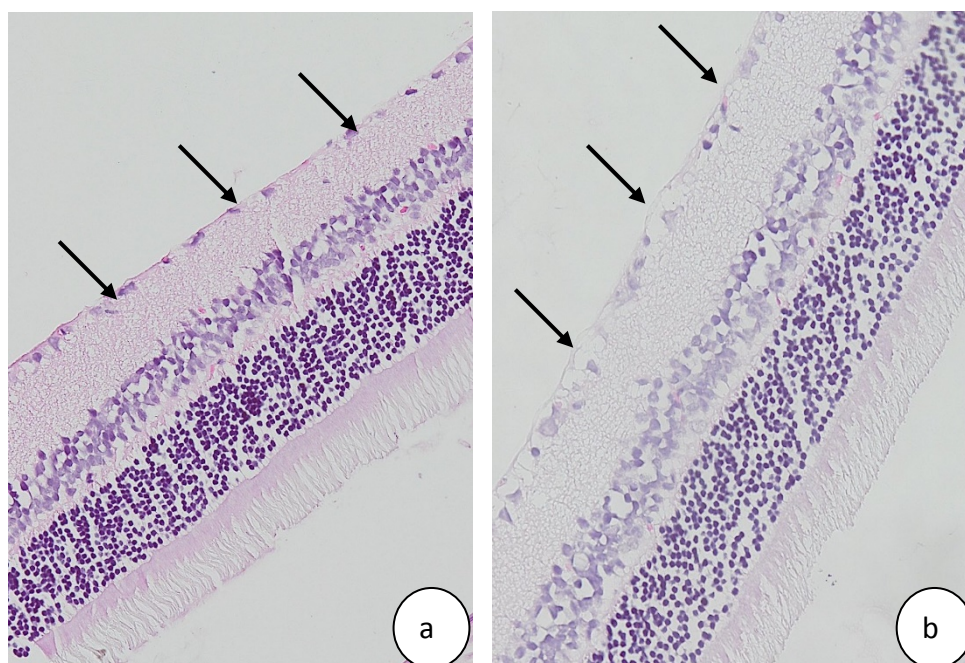


FIG. 3. GANGLIONIC CELL ARRANGEMENT AND RETINAL LAYERS OF CONTROL AND LOW-DOSE STZ-TREATED RATS. (A) THE CONTROL RATS SHOWED A NORMAL RETINAL ARRANGEMENT WITHOUT SWOLLEN OR VACUOLATED CELLS IN THE RETINAL GANGLION LAYER. (B) LOW-DOSE STZ-TREATED RATS SHOWED DISORDERED, SWOLLEN AND VACUOLATED CELLS IN THE RETINAL GANGLION LAYER.