

Variations of Fissures and Lobes of the Lungs in Human Cadavers in Selected Universities of Ethiopia

1. Azmera Gebregziabher

Lecturer of Anatomy
College of Health Sciences
Aksum University, Ethiopia

2. Tesfamichael Berhe

Lecturer of Anatomy
College of Health Sciences
Mekelle University, Ethiopia
Email- anatmek2@gmail.com

3. Peter Ekanem

Associate professor of Anatomy
College of Health Sciences
Mekelle University, Ethiopia

ABSTRACT

Background: The fissures in lung enhance uniform expansion. These fissures may be complete, incomplete or absent. A detailed knowledge of variations of classical and accessory fissures is necessary for proper radiological interpretation and guide to cardiothoracic surgeons performing segmental lung resections, lobectomies to have an uncomplicated perioperative outcome.

Objective: To assess the variations in presence and completeness of fissures and lobes of the lungs in human cadavers in selected universities of Ethiopia.

Method: A descriptive study design was employed to assess the variations in absence and completeness of fissures and lobes of the lung in human cadavers. 43 lungs (23 right and 20 left) of formalin fixed Ethiopian cadavers were used for this study, obtained from dissection rooms of Mekelle, Bahrdar, Gonder Adigrat and Wollo universities. The lung specimens were meticulously observed for the patterns of lobes and fissures, variations were noted and specimens were photographed.

Result: 17.39% right lungs showed absence of horizontal fissure while no specimen showed absence of oblique fissure on both sides. 35% of left lungs had incomplete oblique fissure compared to 47.82% of the right lungs. In addition, 2 right sided and 3 left sided lungs showed presence of accessory fissure and accessory lobe.

Conclusion: Comparison with other studies shows wide regional variations in morphological patterns of lung fissures and lobes, implying environmental and genetic factors in its development. Knowing the frequency of occurrence of a variant fissure in a particular population can help the radiologist and clinician to make correct diagnosis, plan, execute and modify a surgical procedure depending on the merit of the case.

Key words: Lungs, Fissures, Lobes, Variations

INTRODUCTION

Lungs are a pair of respiratory organs situated in the thoracic cavity. Amongst the pair of lungs, the right lung is broader and heavier than the left lung [1]. Two fissures oblique and horizontal, divide it into three lobes namely, upper, middle and lower. The oblique fissure separates the lower lobe from the remaining two lobes. It runs obliquely and crosses the inferior border of the lung about 7.5 cm behind its anterior end. The horizontal fissure separates the upper and middle lobe. It begins from the oblique fissure, runs horizontally and cuts the anterior border at inner end of fourth costal cartilage [2]. The longer and lighter left lung is divided into a superior and an inferior lobe by an oblique fissure which extends from costal to medial surfaces of the lung both above and below the hilum. It begins on the medial surface posterosuperior to the hilum, runs obliquely upwards and backward to cut the posterior border of the lung about 6 cm below the apex and then passes downward and forward across the costal surface. The more vertical left oblique fissure is approximately indicated by vertebral border of scapula in fully abducted arm [3]

Finding accessory fissures in lung specimens is not uncommon, but appreciating them on radiographs and CT scans is difficult and hence they are either not appreciated as distinct entities or are completely misinterpreted.

They usually occur at the boundaries between bronchopulmonary segments. The commonly found accessory fissures are superior accessory fissure, inferior accessory fissure and left minor fissure [4]

Lung develops as an endodermal diverticulum at about 28 days after fertilization. The lung bud bifurcates into 2 main bronchi left and right which ultimately develops into secondary bronchi and the lung lobes. In prenatal life fissures separate individual bronchopulmonary segments. All fissures gradually get obliterated leaving behind oblique and horizontal fissures [5]. Any variation in the morphological pattern of the fissures indicates variations from normal pattern of development of lung. Hence, detection of any accessory fissure is indicative of persistence of those prenatal fissures [6]

The fissures may vary in the degree of completeness and tend to divide the lobe into smaller subdivisions. Complete fissures show continuity of lobes at their bottom only by the parts of bronchial tree and blood vessels. In the region of incomplete fissures the adjacent lobes are connected by a sizeable chunk of pulmonary tissue as the cleft fails to reach the hilum.

The fissure may be absent altogether [7]. The fissures are conducive to uniform expansion of lobes. They provide routes for movements of lobes in relation to each other. This is more relevant to distension and movement of the lower lobes during breathing. The appearance of accessory lung fissure varies on X-ray and CT scan. This is seen especially in reference to depth or completeness of the fissure. A fissure appearing complete on X-ray might be seen as an incomplete one on CT scan and vice versa may also be seen [8].

The knowledge of anatomical variations of lobes and fissures of the lung is important for identifying precise location, extent and morphology of bronchopulmonary segments.

Hence this study aims to find variations in the morphology of lung fissures and lobes of human cadavers and comparing the findings with previous studies.

The fissures of lung help in the movement of lobes in relation to one another, which will accommodate the greater distension and movement of the lobes during respiration and hereby helps in uniform expansion of lung. These fissures may be complete, incomplete or absent. Other than usual fissures, the lungs may also have accessory fissure which may be single or multiple dividing the lungs into many lobes [9].

In many diseases, segmental localization is a must and the knowledge of accessory fissure is of much clinical importance to the clinician. Pre operative planning and strategy for pulmonary lobectomy and segmental resection may also change during presence of such accessory fissures. An incomplete fissure is also a cause for post operative air leakage [10]. Often this accessory fissure acts as a barrier to infection spread, creating a sharply marginated pneumonia which can wrongly be interpreted as atelectasis or consolidation. In X ray, incomplete fissures always give an atypical appearance of pleural effusion. Many times, the accessory fissures fail to be detected on CT scans, because of their incompleteness, thick sections and orientation in relation to a particular plane [11]

Occasionally an extra fissure divides a lung or a fissure is absent. The most common accessory lobe is the azygos lobe, which appears in the right lung in about 1% of people. In these cases, the azygos vein arches over the apex of the right lung and not over the right hilum, isolating the medial part of the apex as an azygos lobe [12]. As in stated in a study [13] of the 50 left sided lung specimens only 44 % (22) had classically complete oblique fissure. Rest showed various degree of parenchymal fusion along the course. In 8% (4 specimens) no oblique fissure could be detected. In 66.66% (16) of specimens on the left were incomplete at both ends. Of the 52 right sided lung specimens 26.92 % (14) had classically complete oblique. In 11.54 % (6) no oblique fissure could be detected, rest were incomplete either at its beginning or at its end or both. The fissures were of 30.15 ± 6.26 cm length when all the lungs with oblique fissure were considered. Maximum depth of the oblique fissure was 5.73 ± 1.41 cm. In one right lung oblique fissure ended on the costal surface 7 cm away from the hilum at its lower end. Horizontal fissure was completely absent in 34.62% (18). In those specimens where horizontal fissure was present 38.89% was incomplete. In another finding [9] it is stated that the horizontal fissure was absent in 7 right-sided lungs (14%) and hence middle lobe was not appreciated. The horizontal fissure was incomplete in 8% of lungs and oblique fissure was incomplete in 6% of lungs. In 2% of the specimens, the oblique fissure was absent. Totally, out of 50 right lungs, 34 lungs (68%) exhibited the normal pattern of fissures and lobes. 9 lungs (18%) out of 50, showed presence of accessory fissures. One specimen showed separation of four bronchopulmonary segments visible on diaphragmatic surface, by formation of accessory fissures. The oblique fissure was incomplete in 12% of specimens and 29 out of 50 left-sided lungs (58%), exhibited the normal pattern of fissures and lobes. 20 specimens (40%) showed presence of accessory fissure. One specimen showed separation of four bronchopulmonary segments visible on diaphragmatic surface, by formation of accessory fissures. A study reported that the horizontal fissure was absent in 5 right-sided lungs. The horizontal fissure was incomplete in 19 lungs and oblique fissure was incomplete in 11 lungs. In 2 of the specimens, the horizontal fissure was absent and the oblique fissure was incomplete. Totally, out of 30 right sided lungs, only 4 lungs exhibited the normal pattern of fissures and lobes. One of the lungs showed an

accessory fissure. The oblique fissure was incomplete in 14 left sided lungs and hence 16 out of the 30 left-sided lungs exhibited the normal pattern of fissures and lobes. Three of them showed an accessory fissure. [14]

As in George *et al.* 2014, among the 65 right lungs, 2 lungs (3.07%) showed absence and 23 (35.38%) showed incomplete horizontal fissures. Three right lungs (4.61%) showed 3 fissures and 4 lobes. Among the 73 left lungs, 11 (15.06%) showed incomplete oblique fissure. Two of them (2.73%) showed 2 fissures and 3 lobes. Accessory fissures are found occasionally subdividing one of the otherwise normal lobes of the lung. Such fissures are found far more frequently in the right lung than the left, and they also tended to be deeper in the right lung. They are more common in fetal and neonatal lung specimens than in adult lung specimens. [15] During the development, the lung tissue grows as multiple bronchopulmonary buds with fissures separating individual bronchopulmonary segments. Later, the fissures separating individual bronchopulmonary segments become obliterated except the major (oblique) and minor (horizontal) fissures in a fully developed lung. Accessory fissure results from non-obliteration of spaces, which are normally obliterated. Common accessory fissures include the inferior accessory fissure (demarcates the medial basal segment of the lower lobe), left minor fissure (demarcates the lingula), and superior accessory fissure (demarcates the superior segment of lower lobes) [16]. Muller *et al.* 2001 in their radiological study observed that the SAF (superior accessory fissure) was rarely seen on radiographs and CT scans while the IAF (inferior accessory fissure) could be seen on approximately 8% of chest radiographs. [17] In the study of Nene *et al.*, 2011, the SAF was seen in 4 of lungs on right and left sides, respectively and IAF was found in 14% and 24% on right and left sides, respectively and left minor fissure (LMF) was seen in 26% of lung specimens. They also observed the presence of accessory fissure and lobe in the lower lobe of two right-sided lungs. The length and depth of those fissures were 6cms and 1cm. Esomonu *et al.* 2013 found three incomplete variant fissures in the right lung and the left lung presents one variant transverse fissure. [18]

Considering the clinical importance of such anomalies and variations, prior awareness and anatomical knowledge of the absence and completeness of fissures and lobes in the lungs is essential for all medical personnel.

The aim of this study is to describe variations in fissures and lobes of the lungs in human cadavers in selected universities of Ethiopia.

METHODS AND MATERIALS

A descriptive study design was employed to assess the variations in presence and completeness of fissures and lobes of the lung in human cadavers. Lungs of formalin fixed Ethiopian cadavers which were used during routine dissection for the medical undergraduate classes in department of anatomy of Mekelle, Adigrat, Wollo, Bahrdar and Gonder universities were used for this study. The study was conducted from November 2014 to January 2015. The study was conducted in Mekelle, Gonder, Bahrdar, Adigrat and Wollo Universities, College of Health Sciences, Departments of Human Anatomy dissection rooms.

A total of 43lungs (23right and 20 left lungs) were taken from the dissection rooms of the five universities selected for this study. 10 lungs (4 right, 6left) from Mekelle, 8 lungs (4 right, 4left) from Adigrat, 4 lungs (2 right, 2left) from Wollo, 9 lungs (6 right, 3left) from Bahrdar and 12 lungs (7 right, 5left) from Gonder universities were examined. All lungs of cadavers found in dissection rooms of Mekelle, Gonder, Bahrdar, Wollo and Adigrat universities were included in the study. Lung specimens damaged during removal or dissection were not included in the study. Two lungs were excluded due to this reason. The lobes and fissures of the lungs were observed for presence of variations in morphological features (i.e., complete, incomplete or presence, absence) and presence of any variant fissure, accessory fissure was noted in the format prepared for data collection and specimens were photographed.

The anatomical classification proposed by (Craig and walker, 1997) was followed to determine for the presence and completeness of fissures. It includes 4 grades. Grade I: complete fissure with entirely separate lobes; Grade II: complete visceral cleft but parenchymal fusion at the base of fissure; Grade III: visceral cleft evident for a part of fissure; Grade IV: complete fusion of lobes with no evident fissural line.

To conduct this research permission was obtained from the College of Health Sciences Ethical Review Committee (ERC) of Mekelle University. Formal letter of cooperation was written for the universities selected for data collection.

RESULTS

Right Lungs

Out of the 23 right sided lung specimens, 12 lungs (52.17%) had classically complete oblique fissure (Table-1). 11(47.82%) were incomplete either at its beginning 3(27.27%) or at its end 4(36.36%) or both 4(36.36%). Horizontal fissure was completely absent in 4 right sided lungs (17.39%) and hence the middle lobe was not appreciated. In those specimens where horizontal fissure was present 13 (68.42%) was incomplete and hence the lobation was imperfect. 2 lungs (8.69%) out of 23, showed presence of accessory fissure and accessory lobe.

One specimen showed separation of four lobes, in which the lower lobe was divided into two by formation of accessory fissure (Fig-4). One specimen also showed separation of four lobes, in which the middle lobe was divided into two by formation of accessory fissure (Fig-5).

Table-1- Comparison of oblique fissure of lungs

Lung	Complete (%)	Incomplete (%)	Absent (%)
Left (n=20)	65%	35%	0
Right (n=23)	52.17%	47.82%	0

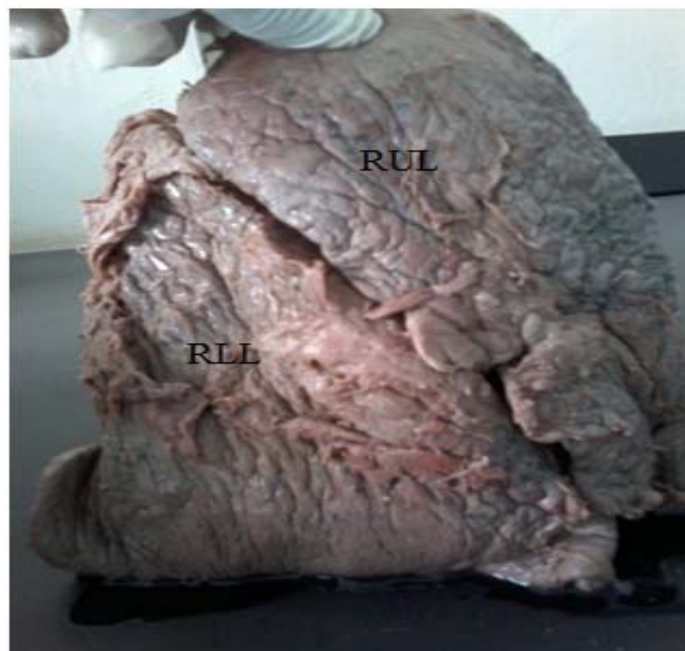

Fig.1. Absence of horizontal fissure in right lung



Fig.2. Absence of horizontal fissure in right lung



Fig-3- Right lung showing incomplete horizontal fissure

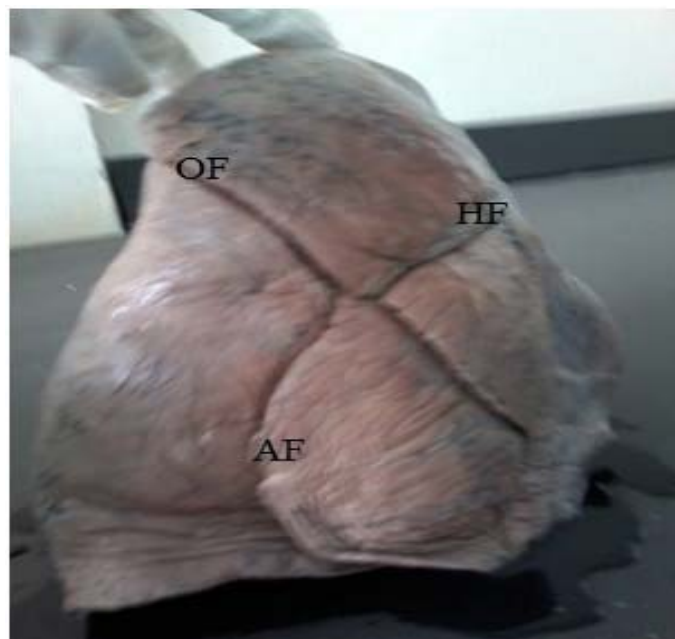


Fig-4- Right lung showing an accessory fissure in the lower lobe and four lobes

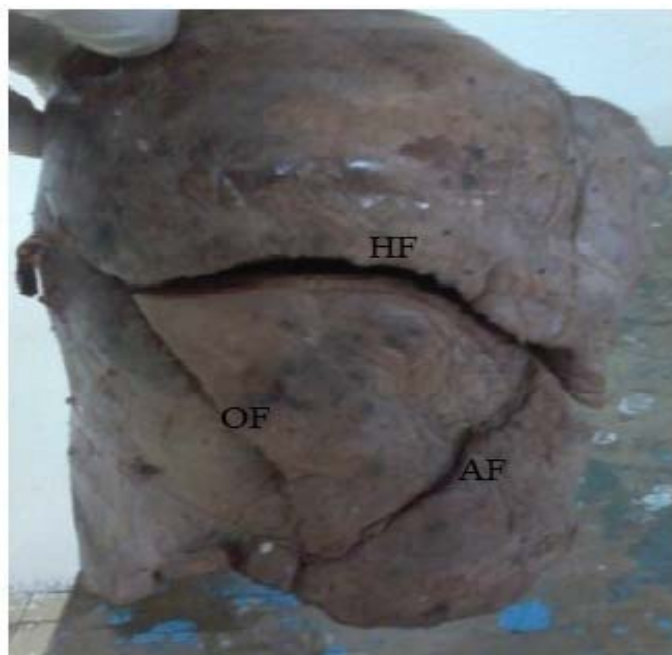


Fig-5- Right lung with accessory fissure dividing the middle lobe into additional lobe

Left lungs

Out of 20 left sided lungs 13 (65%) exhibited the normal pattern of oblique fissure. Rest showed various degree of parenchymal fusion along its course. The oblique fissure was incomplete in 7(35%) specimens either at its beginning 2(28.57%) or at its end 2(28.57%) or both 3(42.85%). Accessory fissure was noted in 3 (15%) of the specimens. In the two specimens the accessory fissure divides the left upper lobe into an additional incomplete middle lobe or cleft upper lobe (Fig-8&9). In the rest one specimen the accessory fissure was present in the left lower lobe (Fig-7).

Table-2- Comparison of incompleteness of oblique fissure

	Incomplete at upper end	Incomplete at lower end	Incomplete at both end
	No (%)	No (%)	No (%)
Right lung (n=11)	3(27.27%)	4(36.36%)	4(36.36%)
Left lung (n=7)	2(28.57%)	2(28.57%)	3(42.85%)

Table -3- Incidence of accessory fissures in the left and right lungs

	Right lung	Left lung
Accessory fissure	2(8.69%)	3(15%)



Fig-6- Incomplete oblique fissure (IOF) of left lung

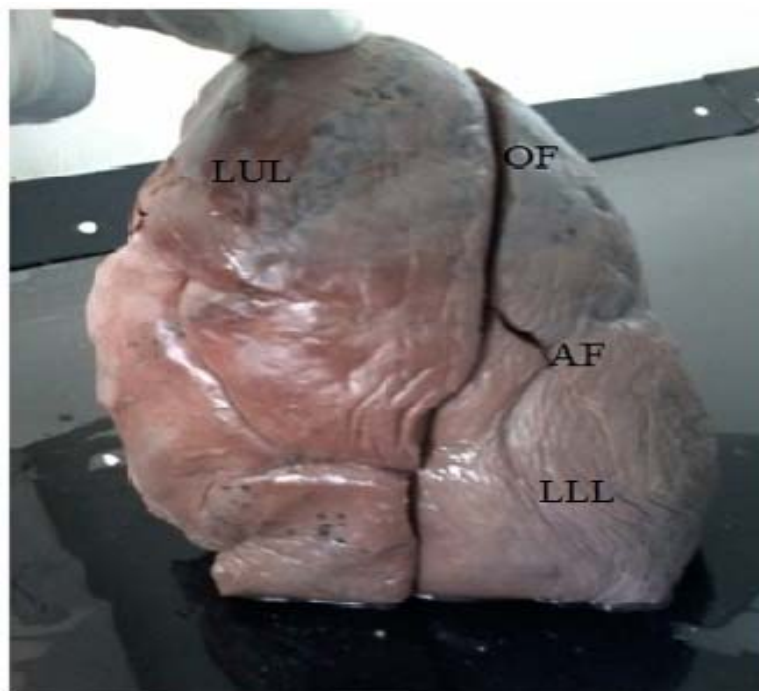

Fig-7- Left lung having accessory fissure in the lower lobe



Fig-8- Left lung with accessory fissure in the upper lobe

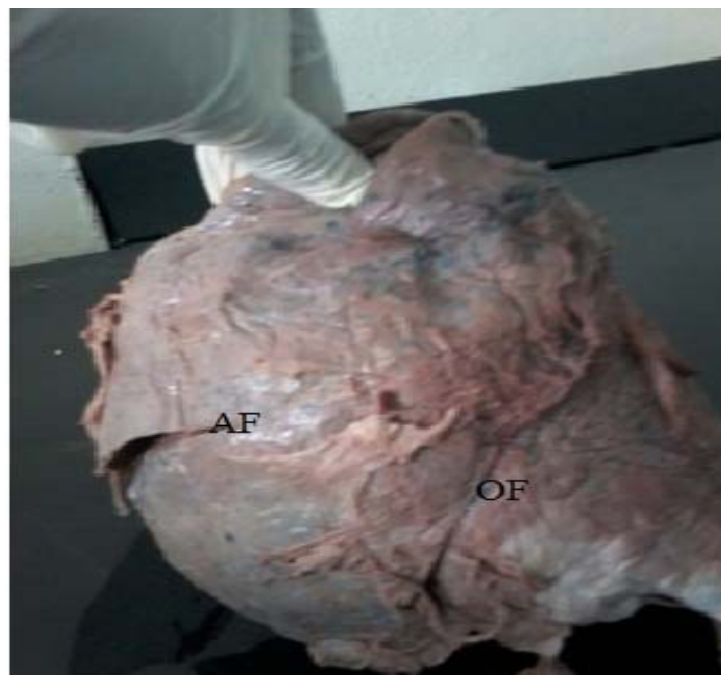

Fig-9- Left lung showing accessory fissure in the upper lobe and three lobes

DISCUSSION

The findings of the present study are being compared with previous research works by different authors. Prevalence of absent horizontal fissure of the right lung in this study shows similarity with some studies [20 ; 9], where as it was less prevalent than in few findings [1,3,18] although it was greater than in reports published by other authors [2,13,17,19,22]. In these right lungs only two lobes can detected due to the absence of horizontal fissure. Present study revealed higher prevalence of incomplete horizontal fissure of the right lung than various previous studies.

Table -4-Comparison of percentage of incomplete and absence of natural fissures by different authors with present study

	Author(s) & Year					
	Varalakshmi et al. 2014	Dutta et al.2013	Kaul et al.2011	Meenakshi et al. 2004	Devi et al.2011	Present study
Right lung						
Oblique fissure						
Incomplete	16.7%	61.54%	24%	36.6%	9%	47.82%
Absent	0	11.4%	8%	0	0	0
Horizontal fissure						
Incomplete	30%	38.89%	32%	63.3%	18%	68.42%
Absent	10%	34.62%	40%	16.6%	9%	17.39%
Left lung						
Oblique fissure						
Incomplete	29.4%	48%	40%	46.6%	36%	35%
Absent	3%	8%	0	0	9%	0

In the present study prevalence of incomplete oblique fissure of the right lung was greater than in previous works [2, 3, 6, 18, 19]. On the other hand it was less prevalent than in [1]. This study reported greater prevalence of incomplete oblique fissure of the left lung than the reports published by [2-3,13,20]; where as it provided a lower prevalence than works by [1,9,18] but it shows similarities with findings of [17,19].

Defective pulmonary development will give rise to variations as encountered in fissures and lobes. Incomplete or absence of oblique and horizontal fissure could be due to a defect in the obliteration of the prenatal fissures either completely or incompletely. An incomplete fissure is a cause for postoperative air leakage during lobectomies and also causes the odd appearance of fluid tracking within the fissure. Incomplete fissures may also alter the spread of disease within the lung [21]. Comparison between right and left lungs from present study reveals higher incidence of incomplete oblique fissure in the right lungs than the left lungs. Similar findings were found from [1, 3, 19]; whereas majority of the previous studies found higher prevalence of incomplete oblique fissure in the left lungs than the right. Absence of oblique fissure was found to be similar among the right and left lungs, in that absence of oblique fissure was not detected in both lungs. [9,] also report no absence of oblique fissure in the right and left lungs. [17, 25] in the right lung and [18] in the left lung did not found absence of oblique fissure in their studies. Parenchymal fusion of various extents is more commonly seen on the right side in comparison to the left side. Surgeons approach to ligate the vessels and bronchi through the depth of the fissure. But otherwise the lung parenchyma has to be dissected to reach those structures leading to preoperative hemorrhage and more postoperative complications. The accessory fissures of the lung are commonly observed in lung specimens, but are often unappreciated or misinterpreted on radiographs and CT scans. Accessory fissures when present at abnormal locations in the lungs give rise to abnormal lobes of the lung aerated by normal bronchus. Accessory fissures can be mistakenly confused with areas of linear atelectasis, pleural scars, or walls of bullae. From a radiological point of view, an accessory fissure may commonly be misinterpreted as a lung lesion. On CT scans accessory fissures are seen as high attenuation curvilinear band. This knowledge of anatomy may help clarification of confusing radiographic findings like extension of fluid into an incomplete major fissure or spread of various diseases through different pathways [4].

In the present study accessory fissure was more commonly observed in the left lungs than the right lungs. Similarly all the compared studies show high prevalence of accessory fissure in the left lung except in [23] which found greater prevalence in the right lung. In patients with endobronchial lesion, an accessory fissure might alter the usual pattern of lung collapse and pose difficulty in diagnosing a lesion and its extent by giving

an unusual appearance. Pneumonia in a particular lobe is contained within the confines of the lobe by complete and normal fissures. In patients with incomplete fissures, pneumonia may spread to adjacent lobes through the parenchymal continuation [21]

CONCLUSION

In conclusion the present study unfolds higher prevalence of incomplete horizontal fissure of the right lung than the previous studies. Incidence of incomplete oblique fissure was found to be greater in the right lung than the left lung and absence of oblique fissure was not found in both lungs. Current study also reveals greater prevalence of accessory fissure in the left lung than the right lung. The results of present study and their comparison with the previous works show that there is a wide range of difference in occurrence of major, minor and accessory fissures between and among different populations. Knowledge of such variations might explain bizarre presentation of certain clinical cases pertaining to lung pathologies. Also knowing the frequency of occurrence of a variant fissure in a particular population might help the radiologist and clinician to make correct diagnosis. Similarly, it might help the surgeon to plan, execute and modify a surgical procedure depending on the merit of the case. This will help to reduce the morbidity and mortality associated with lung surgeries.

Documentation and familiarization of these anomalies remains important for making correct radiological diagnosis and for proper surgical management of lung pathology. Recognition of lung anomalies improves understanding of pneumonia, pleural effusion, and collateral air drift along with disease spreading through lung.

Conflict of interest

The authors declare that there is no conflict of interests regarding the publication of this manuscript.

REFERENCES

- [1] Dutta,S.,Mandal,L.,Mandal,K.,Biswis,J.,Ray,A.and Bandopadhyay, M.(2013).Natural fissures of lung-Anatomical basis of surgical techniques and imaging. National Journal of Medical Research.3 (2); 117-121
- [2] Nene,R.,Gajendra,S.and Sarma,R.(2011).Lung lobes and fissures; a morphological study. International journal of experimental and clinical Anatomy.5; 30-38
- [3] Ghosh,E., Basu,R.,Dhur,A.,Roy,A.,Roy,H. and Biswas,A. (2013).Variations of Fissures and Lobes In Human Lungs-A Multicentric Cadaveric Study from West Bengal, India. International Journal of Anatomy, Radiology and Surgery; 2(1): 5-8
- [4] Godwin, J.D.and Tarver,R.D.(1985).Accessory fissures of the lung. AJR: 144; 39-47
- [5] Sadler T.W. (2004) Langman's Medical Embryology. 9th ed. Lippincott Williams & Wilkins. Baltimore, Maryland. .223-284.
- [6] Varalakshmi, K.L., Nayak, N.J.and Sangeetha,M.(2014).Morphological variations of fissures of lung; an anatomical study. Indian Journal of applied research.4 (8); 467-469
- [7] Modgil,V.,Das,S. and Suri,R.(2006). Anomalous lobar pattern of right lung. Int. J.Morphol., 24(1); 5-6
- [8] Sharma,G.,and Vijayvergiya,T.(2013).Anatomical variations in lobar pattern of lungs; Anatomical study and clinical significance. J Pharm Biomed Sci;26(26); 301 303.
- [9] Meenakshi,S., Manjunatha,Y. and Balasubramanyam,V.(2004).Morphological variations of the lung fissures and lobes. Indian J chest Dis Allied Sci; 46; 179-182.
- [10] Arora,K.,Verma,P.,Kullar,S.,Sharma,K.,Singla,R. and Mahajan,A.(2012).Variations of fissures of lungs. Rev Arg de Aant clin; 4(2);50-56.
- [11] Rodrigues, V., Martins, Y., Guimaraes,C., Santis,M., Marques,A. and Barata, F.(2011).Anatomy for the bronchologist,A prospective study of the normal endobronchial anatomic variants. Revista Portuguesa de pneumologia; 17; 211-5.
- [12] Dutta,S.,Mandal,L.,Mandal,K.,Biswis,J.,Ray,A.and Bandopadhyay, M.(2013).Natural fissures of lung-Anatomical basis of surgical techniques and imaging. National Journal of Medical Research.3 (2); 117-121
- [13] George,B.,M.,Nayak,S.,B.and Marpalli,S.(2014). Morphological variations of the lungs: a study conducted on Indian cadavers. Anat Cell Biol. 47(4): 253–258.
- [14] Muttikkal,T.J., and Deng,C. (2012). Non-azygos accessory fissure in right upper lobe associated with superior and inferior accessory fissures in right lower lobe. J Clin Imaging Sci. 2;79.
- [15] Muller NL, Fraser RS, Colman NC, Pare PD. (2001).The normal chest: Radiologic Diagnosis of Diseases of Chest. Philadelphia: WB Saunders Company; 25-6.
- [16] Esomou,U.,G.,Taura,M.,G., Modibbo,M.,H. and Egwu,A.,O.(2013) Variation in the lobar pattern of the right and left lungs: Australas Med J.6(10): 511–514.
- [17] Devi,B.,Rao,N. and Sunitha,V.(2011). Morphological variations of lung. A cadaveric study in north coastal Andhra Pradesh. Int J Bio Med Res; 2(4); 1149-1152.
- [18] Kaul,N.,Singh,V.,Sethi,R. and Kaul,V.(2014) Anomalous fissures and lobes of human lungs of North Indian population of western U.P. Journal of the anatomical society of india;63;26-30
- [19] Prakash, Bhardwaj,K.A.,Shashirekha,M., Suma H. Y., Krishna,G.G. and Gajendra S.(2010). Lung morphology: a cadaver study in Indian population. Italian Journal of anatomy and embryology; 115(3): 235-240
- [20] Murlimanju,B.,Prabhu,L.,Shilpa,K.,Pai,M.,Kumar,C.,Rai,A.,andPrashanth,K.(2012).Pulmonary fissures and lobes: a cadaveric study with emphasis on surgical and radiological implications. La Clinica Tarapeutica.; 163(1):9-13
- [21] Glazer,H.,Anderson,D.and Dicroce,J.(1991).Anatomy of the major fissure; evaluation with standard and thin section CT. Radiology.180;839-844
- [22] Gesase,A.P.(2006).The morphological features of major and accessory fissures observed in different lung specimens;90(288):26–32
- [23] Varalakshmi, K.L., Nayak, N.J.and Sangeetha,M.(2014).Morphological variations of fissures of lung; an anatomical study. Indian Journal of applied research.4 (8); 467-469
- [24] 18. Muttikkal,T.J., and Deng,C. (2012). Non-azygos accessory fissure in right upper lobe associated with superior and inferior accessory fissures in right lower lobe. J Clin Imaging Sci. 2;79.
- [25] Sreenivasulu,K.,Anilkumar,P.and Gaigwad, R.(2012).Morphological anatomy of accessory fissures in lungs. Indian J Tuberc; 59; 28-31