

VARIATIONS IN ORIGIN OF FEMORAL NERVE FROM THE LUMBER PLEXUS (A CADAVERIC STUDY)

1. Dr. Gurbachan Singh Gindha

Professor, Department of Anatomy, MM Medical College and Hospital, Kumarhatti,
District Solan (Himachal Pradesh).

2. Dr. Deepti Arora

Assistant Professor, Department of Anatomy, MM Medical College Mullana,
District Ambala (Haryana).

3. Dr. Subhash Kaushal

Professor, Department of Anatomy, Government Medical College,
Patiala (Punjab).

4. Dr. Usha Chhabra

Professor and Head, Department of Anatomy, Government Medical College,
Patiala (Punjab).

Abstract:-

The variations in origin of femoral nerve from lumbar plexuses is very much common. The normal root value of origin of femoral nerve is L2, L3 and L4. It can be prefixed or postfixed. Mostly the femoral nerve is used for the nerve block in several surgeries and is vulnerable to compression in tight ilio-psoas compartment. The knowledge of origin and variations of femoral nerve in iliac fossa is important for anatomists, anaesthetists and surgeons to prevent iatrogenic femoral nerve injuries. 30 embalmed with 10% formalin and fixed cadavers were dissected on both sides and 60 lumbar plexuses with their branches formed the material for the study. The psoas major muscle was dissected to see the formation of femoral nerve from the roots and to observe the variations in the formation of femoral nerve. The aim of this study was to look for the variations in origin and branching pattern of the femoral nerve in the iliac fossa and proper exposure of the femoral nerve in the femoral triangle.

Key words: Lumbar plexus, psoas major muscle, iliacus muscle, sacrifice, root value, prefixed, postfixed, inguinal ligament, femoral triangle, iatrogenic injuries.

Introduction:-

The femoral nerve is the nerve of anterior compartment of thigh. It gives muscular and cutaneous branches in femoral triangle. The femoral nerve arises from the lumbar plexus which lies in the substance of psoas major muscle. The lumbar plexus is formed by the anterior rami of spinal nerves L1 to L3 and part of L4. The rest of the anterior ramus of L4 and the anterior ramus of L5 combine to form the lumbosacral trunk. The femoral nerve carries the contribution from the anterior rami of L2 to L4 and leaves the abdomen by passing through the gap between the inguinal ligament and superior margin of the pelvis to enter the femoral triangle on the anteromedial aspect of thigh. In the femoral triangle it is lateral to the femoral artery. The femoral nerve innervates all the muscles in the anterior compartment of the thigh. In the abdomen, it gives rise to branches that innervate the iliacus and pectineus muscles. It also innervates skin over the anterior aspect of the thigh, anteromedial side of the knee, the medial side of the leg, and the medial side of the foot (Drake et al. 2010)¹.

The femoral nerve is the largest branch of the lumbar plexus. The root value of the femoral nerve is L2, L3 and L4. It emerges from the lateral border of the psoas major muscle within the abdomen and passes downward in the interval between the psoas major and iliacus muscles. It lies behind the fascia iliaca and enters the thigh lateral to the femoral artery and the femoral sheath, behind the inguinal ligament. About 4 cm below the inguinal ligament, it terminates

by dividing into anterior and posterior divisions. The femoral nerve supplies all the muscles of the anterior compartment of the thigh and also gives the cutaneous nerves to the thigh. The femoral nerve does not enter the thigh within the femoral sheath (Snell-2012)².

(Romanes-1995)³ described the variations in the origin of lumbar and sacral plexus. He wrote that the lumbar plexus may begin as high as the eleventh thoracic ventral rami or as low as the first lumbar (Eisler-1891)⁴. Similarly the lowest component to join the sciatic nerve may be from the 2nd, 3rd or 4th sacral ventral ramus. He described that the commonest variation is towards the postfixed variety, and some evidence exists that vertebral anomalies (e.g. sacralization of the 5th lumbar vertebra) are often associated. He described the following variations in origin of lumbar and sacral plexuses given in Table-I.

Table-I

Serial number	Name of nerves	Prefixed root value	Normal root value	Postfixed root value
1	Nervus furcalis	L3, L4	L4	L5
2	Obturator nerve	L1, L2, L3	L2, L3, L4	L2, L3, L4, L5
3	Femoral nerve	T12, L1, L2	L2, L3, L4	L2, L3, L4, L5
4	Tibial nerve	L3, L4, L5, S1, S2	L4, L5, S1, S2, S3	L5, S1, S2, S3, S4
5	Common peroneal nerve	L3, L4, L5, S1	L4, L5, S1, S2	L5, S1, S2, S3

The nerve to pectineus arises from the medial aspect of the femoral nerve near the inguinal ligament & passes behind the femoral sheath and enters the anterior aspect of the muscle. (Newell 2005)⁵. Origin of the lateral cutaneous nerve of thigh from the femoral nerve may confuse the practitioners in the treatment of meralgia, paraesthesia.

The femoral nerve breaks up into a sheaf of branches as soon as it enters the thigh, it is more subject to damage by penetrating injuries of the lower abdomen than of the lower limb. Pelvic masses such as a haematoma or neoplasm may affect it, and it has been to be damaged by catheterization of the femoral artery and during laproscopic repair of inguinal hernia. In a complete lesion extension of the knee by the quadriceps muscles will be lost, with some weakness of hip flexion. There is sensory loss over the front of the thigh, with lesions that cause pain in the nerve. The pain may extend as far as the medial side of the foot because this area is supplied by the saphenous branch of femoral nerve (Sinnatamby-2011)⁶.

The femoral nerve block is performed on the main trunk of this nerve just below the inguinal ligament (Ellis et al. 2004)⁷. The higher division of the femoral nerve in iliac fossa results in incomplete femoral nerve block.

Variations are principally due to the variable genetic composition, which is an inheritance carried over from an ancestral origin. Most of the anatomical variations are benign. These muscular variations are due to the errors of embryological development (Ravindranath et al. 2008)⁸. The detailed knowledge of the possible variations in origin of the femoral nerve and the muscles may have immense importance in various pelvic and pelvi-femoral surgeries.

The objective of the present study is to dissect, identify and record the variations in the anatomy of femoral nerve in origin from its root and to compare this study with the previous studies done by other authors.

Material and Method:-

The present study is conducted in the Department of Anatomy of Government Medical College Patiala. The study was done on the embalmed with 10% formalin and fixed cadavers. 30 cadavers, male and female were studied. Out of which 22 were male and 8 were female. The abdomen was opened and psoas major muscle on both sides (right and left) were cleaned and nerves were traced and reached to root of the origin of the nerves by sacrificing the psoas major muscle. The femoral nerve roots were identified and studied the variations in their origin and recorded and photographed and compared the study with the studies done by the other authors.

Observations: -

In the present study the variations were observed in the origin of the femoral nerve. The variations found in 60 cases dissected during the study are described below in (Table-II).

Table-II Variations found in origin of femoral nerve

Root value	Total number of cases/%	Total number of Male cases			Total number of female cases		
		Total male cases/%	Right side cases/%	Left side cases/%	Total female cases/%	Right side cases/%	Left side cases/%
T12, L1,L2, L3, L4	2/3.33	0	0	0	2/3.33	0	2/3.33
L1, L2, L3, L4	30/50	22/36.67	10/16.67	12/20	8/13.33	4/6.67	4/6.67
L1, L2, L3	6/10	3/5	2/3.33	1/1.67	3/5	2/3.33	1/1.67
L2, L3	1/1.67	0	0	0	1/1.67	1/1.67	0
L2, L3,L4	21/35	19/31.67	10/16.67	9/15	2/3.33	1/1.67	1/1.67

The normal root value of the femoral nerve is L2, L3, and L4 but in the present study the following variations were found in the origin of femoral nerve from the lumbar plexuses which are shown in the (Table-II). Table-II The normal root value of femoral nerve is L3 and L4 following variations were found in origin of femoral nerve(Out

Out of 60 cases studied, 22 cadavers were male and 8 cadavers were female and 30 cases were of right side and 30 cases were of left side. Out of 60 cases in two cases (3.33 %) the origin of femoral nerve was from the roots of T1, T2, L1, L2 and L3. Both the cases were of left side and belonged to female cadaver and no such origin was noted in the male cadaver (**photograph-1**).



Photograph-I

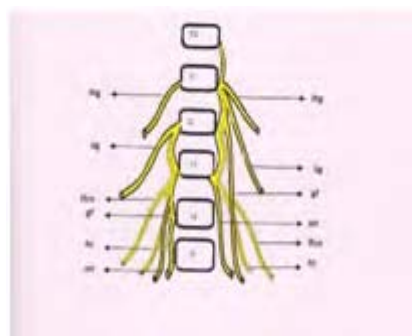


Figure-I

Photograph-I and Figure-I Showing the origin of femoral nerve (fn) from T12, L1, L2 and L3 roots on left side.

The femoral nerve was arising from the roots of L1, L2, L3 and L4 in 30 cases (22 male and 8 female cases) i.e. in 50% of cases. Out of 22 male cases 10 cases (16.67 %) were of right side and 12 cases (20 %) were of left side(**Photograph-II**).



Photograph-II

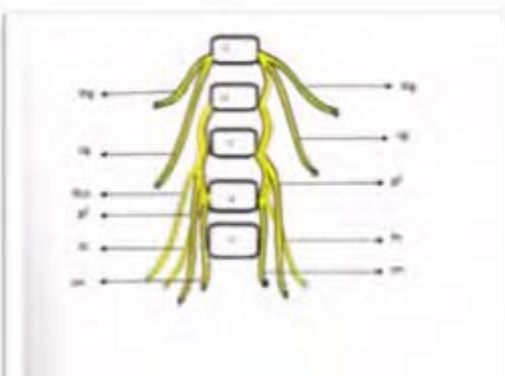


Figure-II

Photograph-II and Figure-II showing the origin of femoral nerve (fn) arising from L1, L2, L3 and L4 roots.

It was found that femoral nerve arising from L1, L2, L3 and L4 bilaterally and in 3 (5%) cases 2 (1.67%) cases (photo-6). In 8 (13.33%) female cases 4 (6.67%) cases were of right side and 4 (6.67%) were of left side. 6 (10.00%) cases of the femoral nerve (3 male and 3 female cases) were taking origin from the roots of L1, L2 and L3. Out of 6 (10%) cases, in 3 (5%) male cases, 2 (3.33%) cases were of right side and 1 (1.67%) cases were of left side and in 3 (5%) female cases the result was the same i.e. (3.33%) of right side, and (1.67%) of left side (**Photograph-III**).



Photograph-III

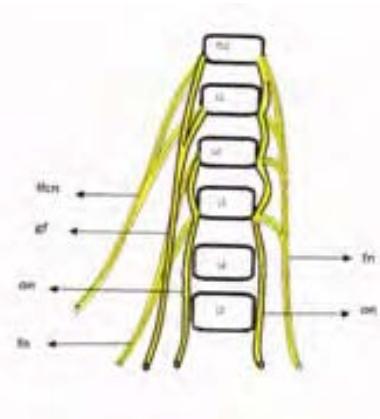


Figure-III

Photograph-III and Figure-III showing the femoral nerve (fn) arising from L1, L2, L3 roots.

One case (1.67%) was arising from the roots of L2 and L3 (**Photograph-IV**). It was found in female and on right side only.



Photograph-IV

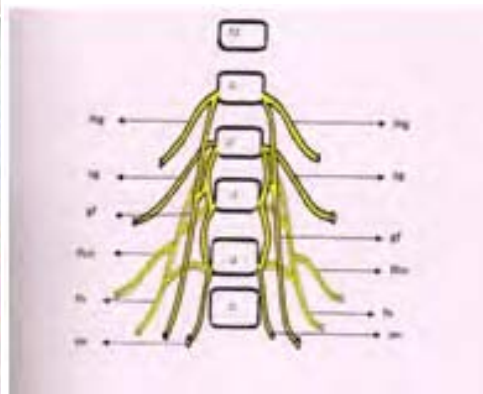


Figure-IV

Photograph-IV and Figure-IV Showing the femoral nerve (fn) arising from L2 and L3 on the right side.

The femoral nerves which were arising from the roots L2, L3 and L4 in 21 (35%) cases were found to be normal in origin. Out of these 21 cases, 19 (31.67%) cases were male (10 cases 16.67% were of right side and 9 (15.00%) cases were of left side) and in 2 female (3.33%), 1 (1.67%) cases of right side and 1 (1.67%) of left side. Out of all 60 cases of femoral nerve origin in 38 (63.33%) cases were prefixed. No case of postfixed was found.

According to (Romanes-1995)³ description the prefixed variety of root value is T12, L1, L2, L3 and L4, whereas postfixed variety the root value is L2, L3, L4 and L5 (Shown in Table-I). According to Romanes (1995)³ definition the nerves arising from T12, L1, L2, L3 and L4 and L1, L2, L3, L4 and L1, L2, L3 all are prefixed variety of nerves whereas the L2, L3, L4 is the normal origin of the femoral nerve (Table-II).

Discussion:-

Bardeen and Elting (1901)⁹ found a contribution from the 1st lumbar nerve to the femoral nerve in 60 percent of the lumbar plexus that they classified as prefixed.

Erbil et al. (1999)¹⁰ described a complex bilateral variations in the formation of lumbar plexus in a 32 years, old male cadaver. On the left side the plexus there was post fixed and

located posterior to the psoas major muscle. The femoral nerve was formed by the union of the anterior rami of the 2nd, 3rd, 4th and 5th lumbar spinal nerves. On the right side, the lumbar plexus was prefixed. The femoral nerve was formed by the branch from the 1st, 2nd, 3rd, 4th and 5th lumbar spinal nerves

(Astik and Dave, 2011)¹¹ reported in this study that the abnormally long L2 root on both sides in a male cadaver. On the right side, it was 92 mm long. After emerging from intervertebral foramen between L2 and L3 vertebrae, it divided into ventral and dorsal division. The ventral division fused with ventral division of L3 and L4 roots to form obturator nerve, and the dorsal division of L2 descended in iliac fossa and fused with combined dorsal division of L3 and L4 to form the femoral nerve, 35 mm above the inguinal ligament on right side. On the left side L2 root was 85 mm long, had the same course as on the right side, and it fused with combined dorsal division of L3 and L4 to form the femoral nerve, 42 mm above the inguinal ligament.

The femoral nerve, the psoas major and iliacus muscles roofed over by the iliac fascia, form a tight fascial compartment, which accounts for femoral nerve lesions due to space-occupying processes in this area. In the cases of femoral nerve paralysis, neuropathy caused by iliac hematoma after anticoagulant treatment (Galzio et al, 1983)¹² or vessel catheterization (Warfel et al, 1993)¹³, the existence of some variant muscles or variations in branching pattern of the femoral nerve may increase the chances of nerve compression.

Analoague and Huijbregts (2009)¹⁴ used dissection of 34 lumbar plexuses to low at the prevalence of anatomical variations in the lumbar plexus and the six peripheral branches from the origin at the ventral roots of T12, L1, L2, L3 and L4 to the exit from the pelvic cavity. The femoral nerve was found to vary in 12 (35.3%) of the investigated lumbar plexuses, In these 12 plexuses, the femoral nerve was observed to bifurcate into two and sometimes three separate slips; in most cadavers, this process occurred within the mid-substance of the psoas major muscle. These slips were separated by the muscle fibers of the psoas major before they rejoined prior to the femoral nerve exiting from the pelvic cavity as it passed beneath the inguinal ligament.

Jakubowicz (1991)¹⁵ investigated the topography of the femoral nerve in relation to components of the iliopsoas muscle in 60 human fetuses. In 3 cases (2.5%) of 120 plexus, a separate band of the lateral fibers of the psoas major passed between the trunks of the femoral nerve. In 3 cases of plexuses, muscular fibers of the iliacus traversed between the trunks of fetal femoral nerve leading to a prevalence of 5% for interactions between the iliopsoas muscle and the femoral nerve.

Spratt et al. (1996)¹⁶ reported that 3 cases out of 136 plexuses (2.2%) contained a variant slip of the iliacus and psoas major muscles that split the femoral nerve.

Jelev et al. (2005)¹⁷ detailed muscular variations of the iliacus and psoas muscles splitting the femoral nerve in a case report. No such split of the muscle was found in the present study.

In the present study the femoral nerve was found prefixed in 39 cases out of 60 lumbar plexuses i.e. in (65%) cases. Out of these, it was found that the femoral nerve arose from T12, L1, L2, L3, and L4 in 2 (3.33%) cases, from L1, L2, L3 in 6 (10.00%) cases, from L1, L2, L3, and L4 in 30 (50%) cases of lumbar plexuses. In 1 i.e. (1.67%) cases it arose from L2, L3. The normal morphological root value of femoral nerve is L2, L3 and L4 was present in 21 i.e. (35%) cases.

Conclusion:-

The knowledge of anatomical variations of femoral nerve is essential for the surgeons to avoid iatrogenic injury to the femoral nerve, for clinicians who are treating patients with meralgia, paraesthesia as lateral cutaneous nerve of thigh may arise from the femoral nerve, for anaesthetics to give successful block in femoral nerve a lateral cutaneous nerve of thigh and for the anatomists to understand morphological in the abdomen and a better knowledge of the regional anatomy and its variations are essential for preventing from the lesions of the branches of the femoral nerve.

References:-

- [1] Drake, RL; Vogl, AW; Mitchell, AWM. Gray's Anatomy for Student's 2' edition. Chapter-lower limb, femoral nerve. Churchill LivingstoneElsevier Canada, Philadelphia, 2010: page537-538.
- [2] Snell, RS. Clinical Anatomy9th edition. Chapter- lower limb, femoral nerve. Lippincott Williams and Wilkins 2012: page463.
- [3] Romanes, J. Cunningham's text book of anatomy, 12th edition. Chapter peripheral nervous system (femoral nerve). Oxford university press, Oxford, New York, Toronto (1995): page 794-795.
- [4] Eisler, P, Des Plexus lumbosacral des Menschen. Anat Anz, 1891; 6: 274.
- [5] Newell, RLM. Pelvic girdle gluteal region and hip joint. In: Gray's Anatomy, Anatomical Basis of clinical practice. S. Standring, Ellis,HJC Healy, D. Johnson, A. Williams, 39thedition. Elsevier ChurchillLivingtone, Philadelphia: 2005; page 1455.
- [6] Sinnatamby CS.Last'sAnatomy (regional and applied).12thedition, Chapter- lower limb, femoral nerve. Churchill Livingstone Elsevier, Edinburg, London, New York, Oxford, Philadelphia, Sydney,Toronto.2011:163-164.
- [7] Ellis, H; Feldman, SA; Harrop, GWD. Anatomy for anaesthetists. 8th edition. Blackwell publishing. Massachusetts, 2004;page 188-191. Cited byRomanes J. Cunningham's text book of anatomy, 12th edition. Chapter peripheral nervous system (femoral nerve). Oxford university press, Oxford, New York, Toronto (1995): 794-795.
- [8] Ravindranath, Y; Manjunath, KY; Ravindranath, R. Accessory origin of the Piriformis muscle. Singapore Med J 2008; 49 (8): 217.
- [9] Bardeen, CR; and Elting, AW. A stastical study of the Variations in the formation and position of the lumbo-sacral plexus in man. Anat. Anz. 1901;19:124, 209.
- [10] Erbil,KM; Onderoglu, S; Basar, R. Unusual branching in lumbar plexus: case report. Okajimas Folia Anat Jpn. 1999 May;76(1):55-59.
- [11] Astik, R B; Dave, U H. Variations in formulation and branching pattern of the femoral nerve in iliac fossa: A study in 64 Human Lumbar plexuses; People's Journal of Scientific Research, July 2011, Vol. 4(2): 14-19.
- [12] Galzio, R; Lucantoni, D; Zenobii, M; Cristuib-Grizzi, L; Gadaleta, A; Caffagni, E. Femoral neuropathy caused by iliacus hematoma. Surgical Neurology, 1983;20(3): 254-257.
- [13] Warfel, BS; Marini, SG; Lachmann, EA; Nagler, W. Delayed femoral nerve palsy following femoral vessel catherization. Archives of Physical Medicine and Rehabilitation, 1993;74(11):1211-1215.
- [14] Analogue, P; Huijbregts, PP. Anatomical variations of the Lumbar Plexus: A Descriptive Anatomical Study with proposed Clinical Implications. J Man Manip 'Ter' 2009; 17(4): 107-114.
- [15] Jakubowicz, M. Topography of the femoral nerve in relation to components of the iliopsoas muscle in human fetuses. Folia Morphol. 1991; 50:91-101.
- [16] Spratt, JID; Logan, BM; Abrahams, PH. Variant slips of psoas the iliacus muscles, with splitting of the femoral nerve. Clin Anat. 1996; 1996:401- 404.
- [17] Jelev, L; Shivarov, V; Surchev, L. Bilateral variations of the psoas major and the iliacus muscles and presence of an undescribed variant muscle-accessory iliopsoas muscle. Ann Anat. 2005; 187:281-286.